

THE RÖNTGEN RAYS IN THORACIC DISEASES.¹

BY FRANCIS H. WILLIAMS, M.D.,
BOSTON.

ABOUT a year ago I had the pleasure of presenting to this Association a paper in which I related some of the early steps in my study² of the adaptation of the x-rays to medical practice; x-ray examinations were then a novelty, but they must now be accepted as a valuable supplement to our other methods of examination. To-day I wish to outline some of the results of the work of the past year, during which I have examined by means of the x-rays more than five hundred patients—about one hundred of which were surgical cases—at the Boston City Hospital and at my office.³ The majority of the four hundred medical cases were suffering from some thoracic disease; certain of these patients—those ill with pneumonia, for instance—have been examined a number of times, as I wished to watch the progress of the disease and see the conditions presented in its different stages.

No harmful effects have been received in any way by these patients, and there need not be the slightest anxiety on the part of any one if proper precautions are taken. I have seen, however, several persons who have suffered a more or less severe inflammation of the skin, the nails also being sometimes involved, but they were all individuals whose occupation brought their hands into close proximity to the Crookes tube, or who, for the purpose of testing its possibilities for harm, had exposed some part of the body to its action at a distance of a few inches for a considerable period; but there are simple ways of obviating these effects.

Before taking up the uses of the x-rays in diseases of the thorax, let me call your attention to one of the principles upon which their usefulness depends.

The varying resistance which the different tissues of the body offer

¹ Presented at the meeting of the Association of American Physicians, May 5, 1897.

² During the progress of this study I have reported my results at medical meetings or by published articles, as follows:

Meeting of the Suffolk District Medical Society, April, 1896.

Meeting and Proceedings of the Association of American Physicians, 1896; "Notes on X-rays in Medicine." Boston Medical and Surgical Journal, October 1, 1896, "A Method for More Fully Determining the Outline of the Heart by Means of the Fluoroscope, together with other Uses of this Instrument in Medicine."

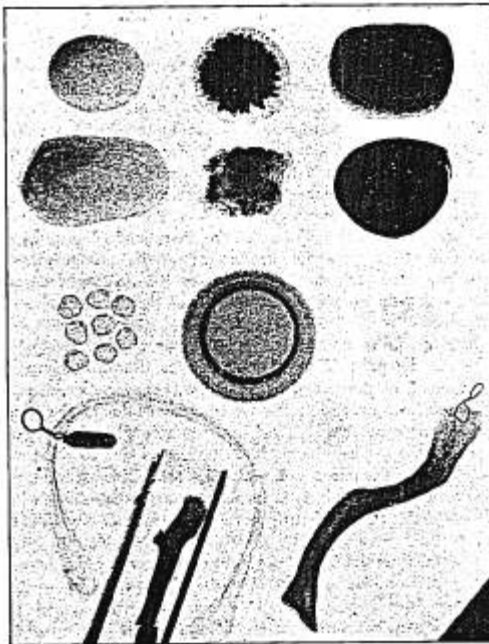
Meetings of the Boston Society for Medical Improvement, and of the Medical Society of the Boston City Hospital, October and November, 1896.

Medical and Surgical Reports of the Boston City Hospital, January, 1897, pp. 134-190. "A Study of the Adaptation of the X-rays to Medical Practice."

³ In making these examinations I have used a Wimshurst machine and an induction coil, but principally the former, both of which were designed by Messrs. C. L. Norton and R. R. Lawrence, of the Massachusetts Institute of Technology.

to the passage of the x-rays depends upon difference in bulk and in chemical composition; organic substances made up of carbon, hydrogen,

FIG. 1




The two upper rows of objects in this radiograph are calculi. The two calculi on the left are composed of uric acid and urates; those on the right of phosphates; and the two in the middle of oxalate of calcium and uric acid, the upper one of these last two having an outside coating of urates. In the centre of the picture is a round aluminum cup, containing water, one inch in depth, and on either side of this cup is a group of gall-stones, and to the right and below the cup a single large gall-stone is seen indistinctly. In the left-hand lower corner is a decalcified bone, bent into the shape of an inverted u, with a lead tag attached by a copper wire. The decalcified bone surrounds an incinerated bone, which is lying on a piece of cotton-wool in a wooden box with a glass side. In the right-hand lower corner is a dry bone; in the extreme right-hand corner is a triangular piece of lead. The picture is reduced to one-half of its original size.

and nitrogen, which have a low atomic weight, allow the rays to pass readily, while those like bone, containing calcium, which has a com-

paratively high atomic weight, offer more resistance to the rays. The soft tissues of the body contain a large percentage of water, and most of them offer about the same resistance as an equal thickness of water. The various fluids found in the body in health and disease, such as the blood, ascitic and pleuritic fluid, pus, urine, fluid from hydrocele, etc., offer about the same resistance as water.

The following experiment with calculi (see Fig. 1) illustrates in a striking manner how important to us is a knowledge of chemical composition in our use of the Röntgen rays in medicine. Before

FIG. 2.



Radiograph of equal bulks of various substances which represent the constituents of the body in a general way:

	Weight.		Weight.
1. Carbonate of magnesium	1.6 grammes.	5. Gelatin	4.0 grammes.
2. Stearic acid	3.8 "	6. Dried egg albumen	6.4 "
3. Oleic acid	3.5 "	7. Carbonate of sodium	5.9 "
4. Palmitic acid	4.4 "	8. Milk sugar	11.7 "
9. Glycerin	4.0 "	13. Phosphate of calcium	2.6 "
10. Water	14.0 "	14. Sulphate of sodium	10.8 "
11. Oxalic acid	12.2 "	15. Magnesium ammonium phosphate	12.5 "
12. Phosphate of sodium	10.6 "	19. Carbonate of calcium	15.3 "
16. Chloride of sodium	8.5 "	20. Fluoride of calcium	11.7 "
17. Sulphur	13.9 "		
18. Chloride of potassium	10.1 "		

attempting to detect any form of calculi in the body I first placed several different kinds over a photographic plate, which was enclosed in dark

paper to shield it from the light, and exposed them for a few minutes to the x-rays. The rays penetrated the calculi made up of uric acid, of cholesterine and biliary salts very readily, but were obstructed by calculi containing oxalate of calcium in considerable proportion, phosphate of calcium, or other inorganic constituents. These calculi were kindly lent to me by Dr. William F. Whitney.

In order to gain some conception of the susceptibility of the various constituents of the body to the x-rays, I made several radiographs of a considerable variety of substances (see Fig. 2), and one of them I have had reproduced here.

This experiment suggests how we may recognize some changes in chemical composition made in the body by pathological processes. The ability to do this without beaker or reagent, or disturbing the vital processes, is a step in the application of chemistry and physics to practical medicine which hints at what the future may have in store for us.

There is one other point which must not be overlooked in this connection, and that is the difference in resistance which air and water offer to the passage of the x-rays. The rays pass through air much more readily than through water, and, as air makes up a certain bulk of the body and a large part of the chest is filled with it, while water enters into the composition of all parts of the body and forms the chief constituent of the soft parts, it is readily seen of how much importance is this difference in permeability of air and water by the rays, on account of the great contrast which is thereby afforded in health between the lungs and their adjacent tissues or organs. Further, as will be shown later, one of the best opportunities for the advantageous application of the x-rays is obtained from the contrast of the normal lung tissue with that offered by pathological conditions which occur in the thorax, involving chiefly increase in density in the lungs or in the space usually occupied by them.

To use the Röntgen rays successfully in practice it is first essential that the physician become familiar with the appearances in the fluoroscope which present themselves in health by examining a number of healthy persons of different ages and weights. This applies particularly to the thorax, and the picture of this part of the body, when seen on the screen of a large fluoroscope, presents so much that it should be studied systematically. The trunk appears lighter above than below the diaphragm, and the rise and fall of this muscle, which is dark in the fluoroscope, are distinctly seen. The chest is divided vertically by an ill-defined dark band, which includes the backbone, on each side of which the lungs, forming the brightest part of the picture, are crossed by the darker ribs; this band varies in width according to the intensity of the light, narrowing as this becomes stronger; with a strong light the vertebrae from the neck to the heart are made out. The pulsating heart is

seen, especially the dark ventricles, the outlines of the *venæ cavæ* and of the pulmonary artery, and under favorable conditions the lighter right auricle. A small portion of one side of the arch of the aorta may be observed in the first intercostal space to the left of the sternum. After this general view has been taken the outline of the lungs should be noted during full inspiration and expiration, and the excursion made by the diaphragm during quiet breathing and during full inspiration and expiration (see Fig. 3).


FIG. 3.

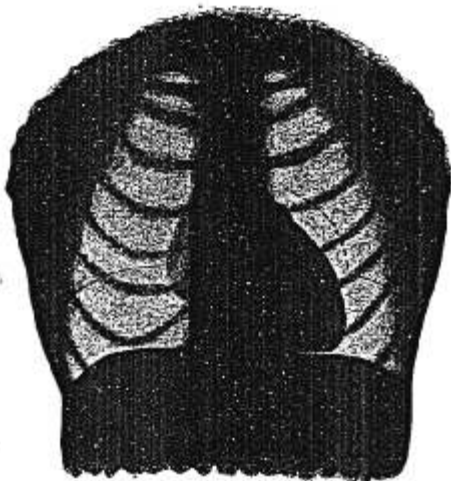

Diagram showing the heart and the outline of the diaphragm of normal chest, as seen in the fluoroscope during full inspiration. The broken lines show position of heart and diaphragm in expiration.

The lungs usually appear brighter during deep inspiration; in young persons brighter than in older persons, as the tissues of the former are more easily penetrated by the rays. In the stout, the lungs appear darker than in the thin, because the outlines are dulled, as it were, by a thicker layer of tissues, which contain much water. It has seemed to me that the right apex is normally darker than the left apex. The normal brightness of the lungs and the normal outlines of the clavicles and ribs should be observed, for, as we note different degrees of pallor by reference to our standard of color in health, in the same way is it

FIG. 4.



The lungs of a patient who died of pneumonia. The lightest portion is healthy. The darker parts have been more affected by the pneumonic process than the lighter.

necessary to know the normal amount of light which should penetrate any given part in order to recognize variations from the normal. The eye must be trained in the use of the x-rays as is the ear for auscultation and percussion, and the fluoroscope, like the ophthalmoscope, should be in constant use in order that the practitioner may not lose any of the skill acquired in interpreting the conditions presented.

To test the possibilities of an examination with the fluoroscope in certain conditions of the lungs, as when congestion or more or less œdema or pleurisy was present, I made one or two simple experiments. On full inspiration in healthy patients I found the pulmonary area lighter than in other stages of respiration, and the ribs stood out in greater contrast, thus showing that there must be less blood in the lung during the former period, and that if any part of the lung is much congested, or if œdema is present, it would naturally appear darker than the normal lung; also when I held a small pasteboard box, about one-half inch deep and full of water, over one side of the thorax of a well-developed and muscular man with a large chest, I could see its shadow in the fluoroscope during about full inspiration, but not at other times.

In order to get further suggestions in regard to the possibilities of the x-ray examinations in diseases of the lungs, I took a number of radiographs of healthy and diseased lungs just after death, which were removed from the body and put over a photographic plate. As a specimen of the latter, see Fig. 4, which shows the lungs of a patient who died of pneumonia. The darker was more affected by the process than the lighter; the lightest portion is healthy. These lungs were kindly sent to me for a few moments by Prof. W. T. Councilman.

Again I examined with the fluoroscope, two days before his death, the chest of A. B., one of my patients who died of syphilis, and found his lungs perfectly clear and the outlines well defined. The outlines, also, of the front and back portion of the ribs forming a lattice-work, as shown in the fluoroscope, were well seen. The autopsy confirmed the examination made by the fluoroscope, and showed that he had perfectly healthy lungs.

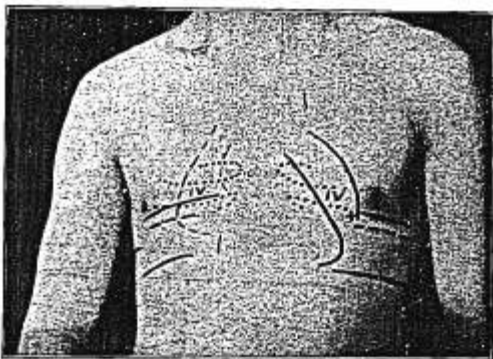
We shall see presently that in certain diseases parts or the whole of one or both lungs appear darker or lighter than in health, and that their volume may be greater or less than in health. The respiratory excursion of the diaphragm may vary from the normal on either or both sides of the chest, in position—that is, it may be higher or lower in the body, and in amplitude, or it may vary in the curve, or its lines may be wholly or partially obliterated.

In making examinations of the lungs, changes in the amount of light seen in the fluoroscope should be carefully observed: for example, whether or not one lung is darker than the other. In pathological conditions the indications of change in density, shown usually by dimin-

ished brightness, may be estimated by comparing the two sides and observing whether the outlines of the organs and whether the ribs and clavicles are more clearly seen on one side than on the other. When both sides are diseased the opportunity for direct comparison with the normal is lost, and one is obliged to depend upon the recollection of the normal in an individual of the same build. The position, excursion, and curve of the diaphragm should also be carefully noted, as compared with the normal.

In six men with healthy lungs the diaphragm moved over an average range of two and three-fourth inches on the right side and two and one-half inches on the left side. (See Fig. 5.) The maximum excursion in any healthy person I have examined was four inches. In eighteen patients with tuberculous lungs the average excursion of the diaphragm was one and one-fourth inches; in some cases less than half an inch.

FIG 5.




Chest of healthy man, aged twenty-one years. Examination with the fluoroscope: The dotted lines on each side of the chest indicate the outlines of the fourth rib; the full upper horizontal lines on either side of the chest about over the fourth rib, the position of part of the diaphragm in expiration; the broken lines just below these, the height of the diaphragm at inspiration during quiet breathing; the full lines below and parallel to these, the outlines of the diaphragm during deep inspiration. The full curved line which is nearer the left nipple indicates the left border of the ventricle during quiet breathing; the full curved line nearly parallel to this, the left border and apex during deep inspiration.

Patients may be examined standing, sitting, or lying down, with the rays passing through the body antero-posteriorly or from side to side. Most of my examinations have been made with the patients lying on a

stretcher (see Fig. 6), and the Crookes tube on an adjustable holder under the patient. For careful examination of the thorax, for example, the Crookes tube should be about two feet away from the fluoroscope,

FIG. 6.



Showing method of examining a patient who has been brought into the dark-room on the stretcher, on which he lies. The Crookes tube is on an adjustable holder below the patient; the static machine on the table near him. About two inches below the patient there should be a brass plate (not shown in the figure), rather more than a foot square and one-quarter of an inch thick, with a circular opening about six inches in diameter. This plate is attached to a flat iron bar in such a manner that it may be swung horizontally and brought under any part of the body it is desired to examine carefully. The rays pass only through the circular opening, and the part to be specially examined is thus more clearly defined. This metal diaphragm is used after the general examination of the body has been made without it. The plate should be grounded.

and its position should be determined by plumb-lines, so as to bring it immediately under the middle of the sternum, on a level with the fourth rib. The fluoroscope is peculiarly applicable to moving organs, such as

the heart and lungs, and is useful in examining children. I now use this instrument in my office as I do the stethoscope.

Let us now take up individually some of the thoracic diseases, and we will first consider pulmonary tuberculosis.

PULMONARY TUBERCULOSIS.

In this the fluoroscope may suggest disease in the following ways: First, a diminution in the volume of the diseased lung is shown by the position and movement of the diaphragm; this movement may be less than normal on one or both sides, and will be restricted on the lower

FIG. 7.

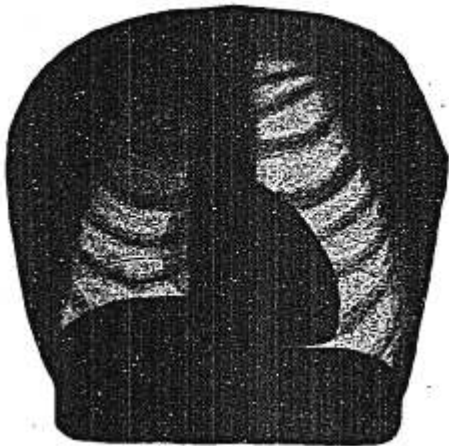


Diagram illustrating appearances seen in the fluoroscope in a case of tuberculosis of the lung. The apex of the right lung is seen to be darker than normal, and the range of movement of the diaphragm on the right side to be less than normal. The position of the diaphragm in full inspiration is shown; broken lines give its position in expiration.

side. Second, an increase in density by diminution in the normal brightness, the degree and extent varying in accordance with the increase in, and extent of, the density. The lung may become so dense that no more rays pass through it than through the liver. The brightness or light in the lungs indicates the amount of air in the chest. The diaphragm lines may be partially or wholly obliterated, as well as the outline of the heart.

I have examined more than one hundred cases of tuberculosis¹ with the fluoroscope, and found a correspondence between the physical signs and the x-ray examination in a considerable number of cases; in certain cases this instrument showed that the disease was more extensive than the physical examination indicated; *in others it showed increase in density in the lungs earlier than was detected by the physical examination; and while in some of these no signs in the lungs were detected prior to those found by the fluoroscope, in others, although one lung was ascertained by the physical examination to be seriously involved, its companion was not suspected until the x-ray examination revealed its increased density.* In most cases of pulmonary tuberculosis the fluoroscope enables us to estimate the amount of lung involved better than any other method of examination. Most of the tuberculous patients that I examined at the Boston City Hospital presented well-marked signs of the disease when they entered, but in private practice the proportion of patients who are seen in the early stage, when there is greater opportunity for successful treatment, is larger; and therefore the fluoroscope might be of special value in these cases on account of the earlier diagnosis it assists us to make.

The following case, which one of my colleagues kindly permitted me to examine with the fluoroscope, shows that this instrument detected increase in density in the right lung when it was not found by auscultation and percussion. It likewise indicates the significance of the diaphragm lines in tuberculosis:

H. A., aged twenty years. Tuberculosis(?). Duration, four weeks; family history not tubercular. Medium dry râles at left apex, with slight dulness; *right apex normal.*

Examination with fluoroscope: Left lung extending to level of the fourth rib very dark; *there is also some involvement of right apex.* The maximum respiratory movement of the diaphragm on the left side is only three-quarters of an inch; *on the right side one inch only.* This is less than half the normal.

[Later tubercle bacilli were found.]

Let me also give the following case in which increase in density was detected earlier by the x-ray examination than by the older method. I examined this patient because he had a pericardial effusion, but the increase in density at the apex of the right lung was so marked in the fluoroscope that it attracted my attention. The usual physical examination was then made, but I could find no evidence of pulmonary tuberculosis. I examined the lungs by the fluoroscope from week to week, and saw that the denser, diseased area extended, while the movements of the diaphragm became less and less on that side. After about six

¹ See "A Study of the Adaptation of the X-Rays to Medical Practice," Medical and Surgical Report, Boston City Hospital, January, 1897, pp. 153-165, for short abstracts of some of these cases, as well as those of pneumonia, etc.

weeks the fluoroscope showed that the left lung also had become denser at the apex, and the excursion of the diaphragm on this side was also lessened. No signs were found by auscultation and percussion on this side at this time. There has been no cough, the patient is about as usual in weight, has no night-sweats, and no bacilli have been found; but about two months after his entrance to the hospital he reacted very strongly to tuberculin, and the diagnosis of tuberculosis was established. Four months after entrance: still no bacilli have been found, although many examinations for them have been made. There are, however, some cases where the bacilli are found before marked signs in the lung can be detected by the fluoroscope; it may be that in these cases the disease begins in the larynx.

Again, a woman twenty years old, unusually well developed and nourished, entered the hospital with phlebitis of the leg. Two of her sisters had died of tuberculosis. By auscultation and percussion the heart's area, action, and sounds were normal; resonance and respiration good over the whole of both lungs. After she had been in the hospital two weeks an x-ray examination was made, chiefly because I had established the routine of so examining many of my patients. This examination showed that the maximum movement of the diaphragm on the right side was one and seven-eighths inches, and on the left side two inches. The apices of the lungs were darker than normal on both sides, more so at the right apex than at the left. The outline of the heart showed that this organ was smaller than normal. Tuberculin was given and was followed by a typical and well-marked reaction. The tubercular family history, diminished movement of the diaphragm, increased density of the apices of the lungs, and the small heart, all pointed to the diagnosis of tuberculosis, and this was confirmed by the tuberculin-test. As yet there have been none of the ordinary symptoms or signs of disease of the lungs, except those seen in the fluoroscope.

We can detect an abnormal condition of the lung in some cases of tuberculosis earlier by means of the fluoroscope than by auscultation and percussion. How much earlier these signs can be anticipated depends upon the rapidity of the progress of the disease, and this varies in different persons and under different conditions. Of course, a diagnosis of tuberculosis is not made by the appearances in the fluoroscope alone, they simply indicate an abnormal condition of the lungs. I shall consider more fully the use of the fluoroscope in pulmonary tuberculosis in another article.

PNEUMONIA.

I have examined more than fifty patients with pneumonia by the fluoroscope, and some of them, as already stated, a number of times while watching the progress of the disease, and found in a few cases that the

lung had not become normal after months. In patients ill with pneumonia the increase in density in the lungs is very marked in the fluoroscope during the active stage of the disease [Fig. 4 suggests the distribution of the darker areas as seen in the fluoroscope], and by its means we may estimate how large an area of the lungs is involved, and by observing the patients at intervals of two or three or more days, as they improve, we may see the dark areas become lighter and lighter, and finally disappear; and we may see the excursion of the diaphragm, which has been restricted and restricted on the lower side, become gradually longer as the lungs clear up. I have examined patients while they were convalescing from pneumonia, both by auscultation and percussion and by the fluoroscope, on the same day, and while by the former I could not detect that the lungs were denser than normal, I was able to recognize the continued presence of abnormal density by means of the fluoroscope, and even when this was no longer possible I could still easily see by means of this instrument that the diaphragm did not descend to its normal limit, thus showing that the lung was still in an abnormal state. Later the normal limit was reached. This method of examination enables us to judge better than any other when the lungs have cleared up after an attack of pneumonia, and if we can obtain, by means of the fluoroscope, later evidence of the presence of a pathological process during its subsidence than by auscultation and percussion, we may also reasonably expect to recognize its onset sooner, and I am satisfied that we can. Further, this ability to detect that the lungs are in an abnormal state weeks after a physical examination has ceased to indicate it, shows the delicacy of the test, and is an added assurance that we can in some cases of tuberculosis recognize an abnormal condition of the lungs earlier by means of the fluoroscope than by auscultation and percussion. A slight central pneumonia is at times overlooked when its early detection by the fluoroscope might, in certain cases at least, prevent its progress to a more severe attack.

During the past winter I have seen three patients where the diagnosis would have been difficult had not the fluoroscope led to that of central pneumonia; one of these cases was seen by three physicians, and we all failed to make the diagnosis. The examination with the fluoroscope caused me to make a diagnosis of central pneumonia, and the further progress of the case confirmed it.

The following case shows the significance of the diaphragm lines in pneumonia:

L. B., aged nineteen years. Pneumonia. Examination with fluoroscope: On seventh day of disease, right lung dark from middle of first intercostal space to fourth rib; the upper and lower border of this dark area were marked; outlines in chest rather less clear than normal on both sides. Diaphragm moved one-quarter inch on right side, and one

and five-eighths inches on left side. Fifteenth day of disease, diaphragm moved one inch on the right side; two and one-half inches on left side. Nineteenth day of disease, diaphragm moved two inches on right side; two and three-quarter inches on left side; original dark area on right side not so bright as other portions of the lung. On the twenty-second day of the disease, diaphragm moved two and one-half inches on right side and three inches on left side.

The abnormal condition of the lungs in tuberculosis and pneumonia may be shown not only by the obstruction which the affected parts offer to the passage of the rays, but also by the restriction of the excursion of the diaphragm. In some cases the latter is a more delicate test.

PLEURISY.

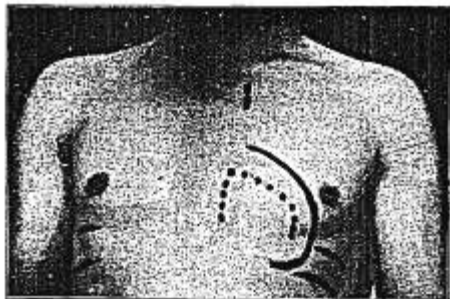
In pleurisy with effusion we can estimate the amount of fluid in a general way by the amount of light which passes through the thorax, and can follow the subsidence of the fluid. When the effusion is large no more rays pass through it than through the liver, and the outlines of the diaphragm, ribs, and heart are obliterated on the side of the effusion. If there is a smaller amount of fluid, the outlines of some of the upper ribs are seen, and with a small effusion the outlines low down in the thorax only are ill defined. The fluoroscope assists us to distinguish between an effusion and a thickened pleura. In some cases of effusion the fluoroscope shows us displacement of the heart, to the left when there is a large effusion on the right side and a much greater displacement to the right, and this displacement is of more frequent occurrence when the effusion is on the left side. This displacement of the heart to the right may not be recognized by percussion even when it has been pushed much beyond its normal place. In one patient the heart was seen to be displaced more than two inches to the right, but no displacement was detected by percussion. While examining some cases of pleurisy with effusion by the fluoroscope, I have found indications of tuberculosis in the lung where it was not previously suspected, and these indications were confirmed later by finding the bacilli or by the tuberculin-test.

EMPHYSEMA.

In emphysema we see in the fluoroscope that the lungs are unnaturally clear and that their volume is increased; the dilated right auricle and pulmonary artery are observed, and the whole enlarged heart is seen more clearly than normal, although by percussion its true outline cannot be determined; it is also seen to lie lower than in health, and in the later stages in a more vertical direction. The diaphragm is seen to be lower than normal, and the excursion which it performs between deep inspiration and expiration to be less than normal. In some cases the emphysematous condition may be greater on one side than on the other.

The lower position and the more limited excursion of the diaphragm give a means of making a diagnosis of this condition probably earlier than has hitherto been possible, or in some cases the lack of these signs enables us to exclude it.

FIG. 8.



Emphysema. Dotted line marks cardiac area by percussion; full line, by fluoroscope. Diaphragm lines, in expiration and inspiration, are shown on each side of chest below the nipple; they are lower and nearer together than normal. Broken line below inner end of left clavicle shows position of arch of aorta.

The following case was sent to me with a diagnosis of emphysema with asthma:

B. F. Examination with fluoroscope: Diaphragm moved on the right side two and one-half inches, and on the left side three inches. The excursion of the diaphragm being normal assures us that no serious amount of emphysema is present.

I have seen patients, both young and old, who complained of getting out of breath on exertion, and the cause in some cases would have been obscure but for the fluoroscope; this instrument showed that the dyspnoea in both young and old was due in some instances to emphysema, and in others to œdema of the lungs.

If some other disease is associated with emphysema, as, for instance, some form of bronchitis, the excursion of the diaphragm is characteristic, but the abnormal clearness of the lungs may be wanting.

BRONCHITIS.

The appearances of bronchitis in the fluoroscope vary; they may differ very little from those in health, or both sides of the thorax may

be less bright than normal. The respiratory movement of the diaphragm was not especially impaired in the cases I have seen.

PNEUMOTHORAX—HYDROTHORAX—PNEUMOHYDROTHORAX—
PNEUMOPYOTHORAX—ŒDEMA OF THE LUNG.

In pneumothorax the fluoroscope shows that the affected side of the chest is lighter than normal, that the heart and vessels may be much displaced, and that the diaphragm is much lower than normal on that side, and has a characteristic curve.

In pneumohydrothorax or pneumopyothorax, when the patient is examined lying down, the whole of the affected side of the chest is seen to be dark; if examined in a sitting position the upper portion of the chest is clear and the lower dark. The appearances remind one of a tumbler half-full of ink; when the patient bends forward or backward the height of the fluid on the chest-wall changes; if the patient is shaken gently the surface of the dark fluid is seen to be agitated. In pneumohydrothorax or pneumopyothorax on the left side the surface of the fluid is seen to be disturbed by the pulsations of the heart.

In hydrothorax and œdema of the lungs the fluoroscope is also of service. In these conditions, as well as in empyœma, the outlines of the diaphragm are wholly or partially obliterated. Some partial œdema of the lungs is, I am inclined to believe, a more frequent condition than has been supposed. On first examining a patient of this class, his condition being unknown, I was surprised to find how difficult was the passage of the rays, and when I saw that the picture of the patient's thorax in the fluoroscope was unusually dark, supposed something was wrong with my Crookes tube; but after trying another I realized that the patient's chest was denser than normal; the tube was not in fault. I have examined a number of cases which illustrate the aid the fluoroscope renders in congestion or œdema of the lungs; this instrument showed that one of these conditions was present when it was not made out by physical signs, and it thus assists the physician to recognize the interference that may occur in the pulmonary circulation in cardiac or renal disease.

I have found it instructive to study, by means of the fluoroscope, cases of dyspœna on exertion, and note the amount of congestion or œdema of the lungs present in them. Cases of this kind have already been referred to under emphysema.

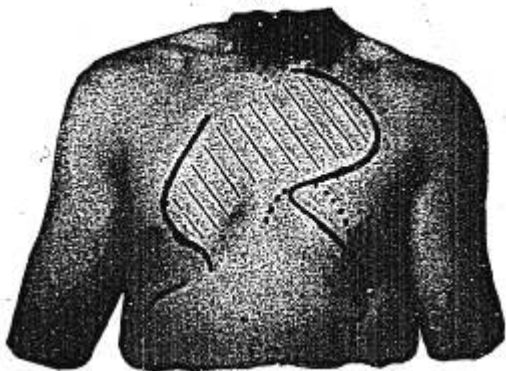
H. E., aged twelve years. Entered the hospital with an old endocarditis following rheumatism. There was a systolic souffle at the apex of the heart transmitted to the axilla; enlarged heart; orthopœna, œdema of the lungs, and intense dyspœna. Digitalis given. Three days after entrance examination with the fluoroscope showed that the lungs were denser than normal below the second rib on the right side,

and the third rib on the left side. Four weeks later, second examination with fluoroscope: Lungs perfectly clear, heart smaller. The patient had been up and about for some time.

ANEURISMS.

I have examined with the fluoroscope and taken radiographs of one subclavian and several thoracic aneurisms. The heart in some of these latter cases was much displaced. Aneurisms of the arch of the aorta are most clearly outlined when their borders are nearest the fluoroscope; those on the left when examined from the back, those on the right when examined from the front. It is obvious that aneurisms of the thoracic aorta can sometimes be detected earlier by x-ray examination than in any other way. In obscure thoracic cases, where an aneurism of certain portions of the aorta is suspected but does not exist, it may be excluded by an x-ray examination.

FIG. 5.



Thoracic aneurism. Examination with fluoroscope: The curved line in the upper part of patient's left chest, and the curved line on his right chest indicate the outline of the aneurism as seen in the fluoroscope. The lower curved line on the left chest marks the outline of the heart; the lowest curve on the right front, part of the outline of the diaphragm; the dotted line, the cardiac area as determined by percussion. This case shows how a large aneurism may exist in the chest without giving rise to marked physical signs.

I have recently seen in consultation a patient who had had excellent advice in Boston and New York, as well as elsewhere, and the diagnosis was obscure until my x-ray examination showed an aneurism of the aorta. In another case my x-ray examination showed that there was no aneurism where it was thought to exist.

FIG. 10.

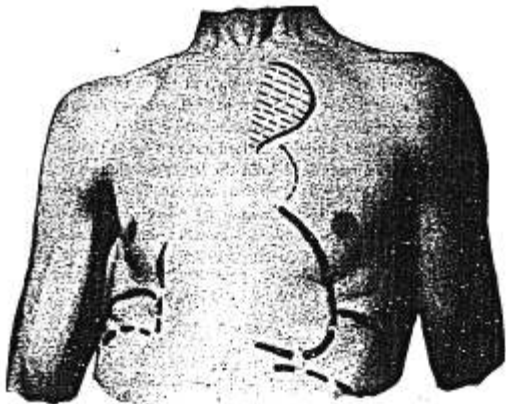


FIG. 11.




Fig. 10 (front) and 11 (back) show a smaller aneurism of the aorta. The arrow in Fig. 11 points to where the pulsation was best seen.

THE HEART.

Let us now consider the position, size, and movement of the heart in health as shown by the fluoroscope, before taking up some of the applications of the x-ray examinations in cardiac diseases. The best view of the heart is obtained during full inspiration, as then the diaphragm is so depressed as to expose a much greater part than during quiet breathing, and with more air in the lungs the outlines of the heart stand out better on account of the greater contrast thus produced. On the left side of the sternum the objects seen most clearly are a considerable part of the ventricle, including the apex, and the pulmonary artery; on the right of the sternum the right auricle, from about the second to the fourth rib, and the venæ cavæ; the right auricle and the venæ cavæ are not so dark as the ventricles, as they are not so thick.

When the space occupied by the lungs is in a normal condition the outline of the portion of the heart on the left of the sternum can be followed by means of the fluoroscope with more certainty, accuracy, and more fully than by percussion. The lower border of the heart near the apex is not obtained by percussion, but part of it is seen in the fluoroscope during deep inspiration. Also, on the right of the sternum the position and size of the right auricle, although it is not distinctly outlined, can be better ascertained by the fluoroscope than by other means; likewise the right border of the bloodvessels, which are much more marked in the fluoroscope than the right auricle; but the right border of the ventricle, being behind the sternum in health, is then better determined by percussion than by the fluoroscope.

The position of the heart varies in health in different persons. With deep inspiration it moves downward and toward the median line nearly an inch. While watching the pulsations of the heart in the fluoroscope I observed that the most marked changes in the outlines were not at the apex, but at the left side at the point corresponding to the cavity of the ventricle, the maximum pulsation being about where the outline of the ventricle crosses the fourth rib. I could see the ventricle contract and expand as it emptied and filled.

The change in the position of the heart, due to conditions outside of itself, such as pleurisy with effusion, pneumothorax, emphysema, etc., may be seen in the fluoroscope, as already stated, or the change in position due to its own enlargement. We may also recognize, for example, enlargement of the ventricles and see a dilated right auricle and pulmonary artery, and pulsations in the venæ cavæ. Differences in size may likewise be observed, for instance, the diminution which is found in anæmic patients with tuberculosis, or increase in size which takes place in hypertrophy or dilatation. The ability to observe such changes

as the above enables us to obtain a more accurate knowledge of the condition of the heart in disease than has hitherto been possible.

The so-called apex-beat, which physicians use so much as a point of reference in examining the heart, is not the apex-beat in all cases, but sometimes an impulse given by the side of the ventricle; the apex of the heart is then seen in the fluoroscope to be lower down, usually much below the point where the impulse is felt on the wall.

Calcareous deposits may be seen in some cases, but at present only when the disease is unusually well marked. In one of my patients I saw a dark area in the aorta, and in portions of the heart contiguous to it, which were pushed over to the right of the sternum. The autopsy showed that this dark area seen in the fluoroscope was a calcareous deposit.

The fluoroscope assists us to make a differential diagnosis between a pericardial effusion and an enlarged heart. Not only are the outlines seen to be different in the two cases, but in pericarditis with much effusion the characteristic pulsations of the heart are not seen.

In some diseases of the heart its outlines, to the left of the sternum, as found by percussion, are not correct. In order to compare the size and position of the heart, as obtained by this method and as seen in the fluoroscope, I drew on the skin the cardiac outlines found by percussion, and directly afterward these outlines as seen in the fluoroscope. I have done this in about thirty cases. Both sets of outlines were then traced on tracing-cloth, held carefully over the skin, the one in red and the other in blue lines. (In other patients I photographed the two sets of lines.) Comparison between these lines showed that in some cases the outlines obtained by the two methods, namely, by percussion and by the fluoroscope, agreed very well; in others the difference was marked. It should be stated, however, that although percussion does not indicate in some cases the true size and position of the heart, a proper examination of this organ with the fluoroscope is difficult to make, needing careful adjustment of the x-ray apparatus and experience with a considerable number of cases.

I have used several methods for recording the outlines of the heart seen in the fluoroscope; one record is made by means of a flexible, fluorescent screen which has a smooth surface like a porcelain slate. The screen is placed on the chest of the patient, the room is darkened, and the outline traced with an ordinary lead-pencil. These lines may be afterward rubbed out with a moist sponge and the screen used again. Another method, alluded to above, and one which allows of a ready comparison of results, is to draw the outlines of the organs on the skin by means of a special pencil, while looking through the fluoroscope, and then to place a piece of tracing-cloth, about a foot square, on the chest, and trace upon it the outlines that have been made on the skin. It is well in

these tracings to include the sternal notch, the nipples, the fourth rib, the ensiform cartilage, and the border of the ribs on either side and below the latter, as these serve as points of reference and comparison. Care must be taken that the tracing-cloth be held smooth and that the skin be not moved or stretched. These cloth tracings may be placed one over another and readily compared, as, for instance, the abnormal with the normal, or the size and shape of the heart in different diseases or in different stages of the same disease.

In the mediastinum new-growths or abscesses may be expected to give evidence in the fluoroscope of their presence by displacing the vessels and changing the normal outlines of the latter before they are large enough to be themselves seen by means of this instrument. "

I wish to point out the advantages that may follow a study of carefully made radiographs. I have taken radiographs that indicate, for example, adipose tissue, the outlines of muscles, tendons, and arteries in healthy persons, both children and adults. Possibly we may by this means obtain useful clinical information as to the condition of the arteries in arteriosclerosis before it is recognized in other ways.

SUMMARY.

No harmful effects have been received by the patients—more than five hundred in number—that I have examined with the x-rays.

The varying resistance which the different tissues of the body offer to the passage of the Röntgen rays depends upon the difference in bulk and in chemical composition.

The difference in permeability of air and water by the x-rays is of great importance in thoracic diseases.

The normal brightness of the chest having been observed in the fluoroscope, the departure from the normal in two directions may be noted by comparison. First, a given part of the chest may be darker than normal on account of the obstruction offered to the passage of the rays, which is due to the *increase* of density that occurs in tuberculosis, pneumonia, infarction, œdema, congestion of the lungs, aneurisms, new growths, or to fluid in the pleural and pericardial sacs, that occurs in pleurisy with effusion and pericarditis with effusion; the distribution, location, and amount of this increase in density which the fluoroscope shows, assists us in some cases to distinguish between these diseases or conditions. Second, a given part of the chest may be brighter than normal, because it is *more* permeable than in health by the rays on account of the *diminution* in density, due in the case of emphysema to increase in the amount of air in the lungs, or, in the case of pneumothorax, to increase in the amount of air entering the thorax and displacing the lung.

Importance of the diaphragm lines: The normal diaphragm lines on both sides of the chest (these include position, excursion, and curve of the diaphragm and the clearness with which they are seen) having been observed in the fluoroscope, departure from the normal may be noted by comparison. In tuberculosis and pneumonia the excursion of the diaphragm is restricted, and restricted on the lower side; in emphysema, on the contrary, although the excursion of the diaphragm is restricted, it is restricted on the upper side—the diaphragm may go lower down toward the abdomen—and in pneumothorax on the affected side it has a characteristic curve and moves only on its median end. In tuberculosis, pneumonia, pleurisy, hydrothorax, empyema, and œdema of the lungs, the diaphragm lines, as well as those of the heart, may be wholly or partially obliterated, owing to the abnormal density of the lungs in their lower portion. In some cases of tuberculosis and pneumonia the lessened range of movement of the diaphragm is a more delicate test than the diminished brightness of the lungs. The normal outlines of the diaphragm may also be changed by an abscess or a new growth contiguous to it.

The fluoroscope gives us better assurance that the lungs are in a healthy condition than other methods of physical examination, and, in connection with auscultation and percussion, teaches us in disease to interpret better the signs found by the older method.

The fluoroscope gives us earlier evidence of disease in some cases of tuberculosis and more accurate information of its extent (this affects the prognosis) than can be obtained by the usual physical examination.

The fluoroscope gives us more accurate information of the extent of the disease (this affects the prognosis) in pneumonia and of the duration of an abnormal condition of the lungs.

It shows a displacement of the heart in pleurisy, which is sometimes not recognized by other means, and assists us to recognize and estimate the amount of fluid in the pleural and pericardial sacs.

It enables us to recognize or exclude emphysema.

It enables us to ascertain the cause in some cases of dyspnoea that would otherwise be obscure.

It assists us to recognize œdema of the lungs, pneumothorax, hydrothorax, and pneumohydrothorax.

It gives us the means of making an earlier and more certain diagnosis of some cases of thoracic aneurism than any other method, and enables us in certain cases to exclude it where it has been suspected but is not present.

It enables us to outline the heart more accurately and completely than has hitherto been possible and to observe certain changes in it; and it especially assists us to a more accurate determination of the

size, movement, and position in disease, and in some cases to observe not only the heart as a whole, but the auricle and ventricle separately. Further, it enables us to recognize earlier associated conditions, such as oedema of the lungs, and assists us to recognize pericardial effusion.

We may sometimes make a diagnosis by an x-ray examination alone, in certain cases of aneurism and emphysema, for example, but it is, as a rule, only one method of examination, and its value in assisting us to establish a diagnosis varies, of course, in different diseases. The x-ray examination should be used in connection with other methods; the information derived from it in suitable cases is more definite and accurate than that obtained from auscultation and percussion. The fluoroscope and the stethoscope aid each other.

As is the case with all other observations on which a diagnosis is founded, the conditions which are revealed by the fluoroscope are only to be rightly interpreted after experience in making x-ray examinations has enabled the physician to give these observations their proper weight.

I have had the privilege of studying the physics of the x-rays in the Rogers Laboratory of the Massachusetts Institute of Technology, and I am under obligation to Professor Charles R. Cross and two of his assistants, Mr. C. L. Norton and Mr. R. R. Lawrence, for their aid in this study. I also desire to express my appreciation of the active interest taken by the trustees of the Boston City Hospital in my work, and the kindness of my colleagues on the staff for affording me an opportunity of examining many of their patients.

THE DIAGNOSIS OF EARLY PREGNANCY.

By THOMAS WATTS EDEN, M.D. EDIN., M.R.C.P. LOND.,
SENIOR ASSISTANT PHYSICIAN CHELSEA HOSPITAL FOR WOMEN, LONDON.

THE student of the diseases of women, and equally the general practitioner, must keep the fear of pregnancy ever before him. As a possible occurrence, it cannot be excluded from his mind, except in the case of old women and little girls, the earliest recorded pregnancy being at the age of eight, the latest at sixty-two years. Within these wide age-limits he must be prepared to meet and recognize it under the most unlikely circumstances; prepossessions must never sway his judgment or lead him to dismiss the eventuality from his mind as impossible, if the logic of physical signs points in its direction. In dealing with the diagnosis of pregnancy it is pre-eminently necessary for the medical man to be sure of himself. Circumstances may arise in which he cannot even mention the matter unless certain of his diagnosis, and nothing brings