DIRECT INTRACARDIAC ANGIOCARDIOGRAPHY-· ITS DIAGNOSTIC VALUE

IGNACIO CHAVEZ, M.D.,* NARNO DORBECKER, :VLD.,* AND ALEJANDRO CELIS, M.D.t

MEXICO, D. F., MEXICO

USING the Forssmann[1,2] technique of heart catheterization, Egaz Manis, Lopo Carvalho, and Alen Saldana[5] injected concentrated solution of iodide through the catheter and with x-ray exposures at the end of the injection obtained beautiful images of the great vessels. They called their method *pneumo-angiography* and in 1931, applied this method to the study of the great vessels in tuberculous patients.

In 1937 Castellanos and co-workers[6-8] published a method by which visualization of the heart chambers could be obtained in living persons. The methc<l consists of rapid injection of radiopaque substance (35 or *50* per cent Per-Abrodil or uroselectan) into the venous blood stream through the antecubital veins, the amount injected varying from 10 to 15 c.c. according to the child's age. Films should be overexposed. This method, angiocardiography, is very useful and has made possible the diagnosis of many congenital heart anomalies.

A year later, in 1938, Robb and Steinberg[9] applied the method to adults. It was necessary to modify the amount and the concentration of the dye, the average amount used being 30 to 40 c.c. of a 70 per cent solution. In addition, by determining the circulatory time (T.C.S.) and filming the right and left chambers at the proper moments, they obtained for the first time the image of the left chambers and the aorta. Unfortunately, the high opacity obtained by Castellanos in children could not be attained in adults. Nevertheless, in some fortunate cases, Robb, Steinberg, Sussman, Taylor, and McGovern and associates[9,11-15] have been able to obtain good diagnostic films of the left atrium in mitral rheumatic heart disease and of the aorta and aortic aneurisms.t

Read at the Inter-American Congress of Cardiology, Mexieo, D. J<', Oct. 5-12, 1946.

*National Institute of Cardiology,

tGeneral Hospital.

tAfter the reading of this paper we received a communication from Dr. Perez Ara[3] of Cuba and the reprint of his paper, "Right Heart Catheterisation," published in July, 1931, in *Revista de medicina y cirugia de la Habana.* Dr. Plirez Ara claims priority for the introduction of the catheter into the right heart through the internal jugular veins. He passed a Nelaton catheter up to the right auricle and, after injecting 20 c.c. of a 50 per cent solution of sodium Iodide he made an exposure at the end of the injection. By this method he obtained very clear visualization of the lung vessels. Dr. Plirez Ara in this experiment, as did Egaz Monis in his *pneumoangiography,* used a normal thoracic x-ray technique. If they had used a more penetrating exposure, they would certainly have obtained the visualization of the heart chambers. This was the fundamental change in technique made by Castellanos and associates.6-8

In 1946 one of us, (A. Celis) who is mainly interested in lung and mediastinal problems, modified the method with good results and applied the modified technique to heart problems.

TECHNIQUE

The reasons why Castellanos' method does not give clear-cut results are the following: (1) the relatively long distance that the opaque substance must travel from the antecubital veins to the heart; (2) too much dilution of the opaque substance with nonopaque blood; and (3) a shunt of the opaque material to undesirable veins.

To avoid these defects it is necessary (1) to put the opaque substance in tr.e place where it is needed, if possible; (2) to fill the part to be visualized completely; and (3) to inject the substance very rapidly to avoid too much dilution.

In addition to these conditions, the opaque substance must be very opaque to x-rays, nonirritating to the endothelium, nontoxic, and easily and rapidly eliminated.

The new method consists of the introduction of a rubber catheter directly into the right atrium, or right ventricle if desired, through the external jugular vein which has been exposed. Fluoroscopic control of the position of the catheter, determination of T.C.S. through the catheter, and a very rapid injection of radiopaque substance are necessary parts of the technique. We commonly use 50 c.c. of 70 per cent solution of diodrast, but we have used as much as 90 c.c. in very large hearts. The injection time should be 0.75 second to 1 second. We take films routinely during or at the end of the injection; others are made according to T.C.S. at intervals of one, two, and three or more seconds. The full technical details are contained in Celis' paper which is in press.

The dissection of the jugular vein and the introduction of the catheter through this vessel might seem dangerous. The procedures are really only impressive; they are not more dangerous than the introduction of a catheter through any other vein. The advantage of the jugular over the antecubital route is that the former permits the introduction of a sufficiently large catheter (number 12 or number 14) to make possible the rapid injection of enough material to produce correct opacification of the heart chambers.

It is interesting to note that in pyelography there have been fatalities. In spite of the fact that highly concentrated dyes are rapidly i_ntroduced while performing angiocardiography, no fatalities are known to have followed this procedure.*

NORMAL IMAGE

The excellent results obtained by these methods are similar to those obtained in post-mortem studies by Chapuon, Laubry, Cottenot, Routier, and Heim de Balsac in adults and by Castellanos in infants.

*After this paper was written, there was a fatal accident at the General Hospital. The patient had advanced rheumatic heart disease, with double mitral lesion and auricular fibrillation. Six hours after angiocardiography was performed, the patient had symptoms of pulmonary embolism and died three days later. Post-mortem"examination could not be made, so we do not know what role the angiocardiography may have played

A careful review and comparison of their results with ours and with those obtained by American authors has enabled us to confirm some known facts and to discover others. The latter will be only briefly referred to in this paper since they will be the subject of more extensive research.

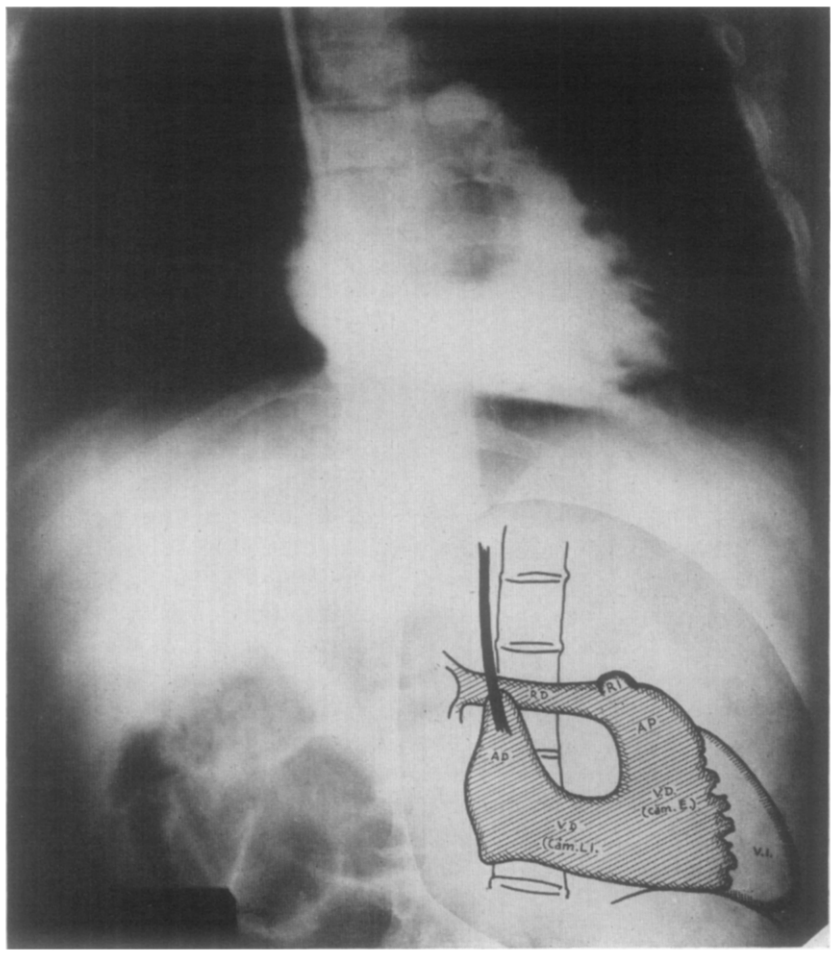

Fig. 1.—Angiocardiogram of right chambers of normal heart.

It is already well established that the right chambers are U shaped (Fig. 1). The superior vena cava and right atrium constitute the right limb of the U. Its projection is a little to the right of the vertebral column, and does not reach the diaphragm. The inflow tract of the right ventricle forms the horizontal limb. The outflow tract of the right ventricle forms the lower two-thirds of the left limb of the U; while the pulmonary artery forms the upper third of this limb. Between the right and horizontal limb, and between the lower two-thirds and

the upper third of the ascending limb there are often seen notches which we think are due to the tricuspid ring and to the pulmonary sigmoid valves respectively. \Ve wish to point out (Fig. 2) that the pulmonary artery itself is not so near the

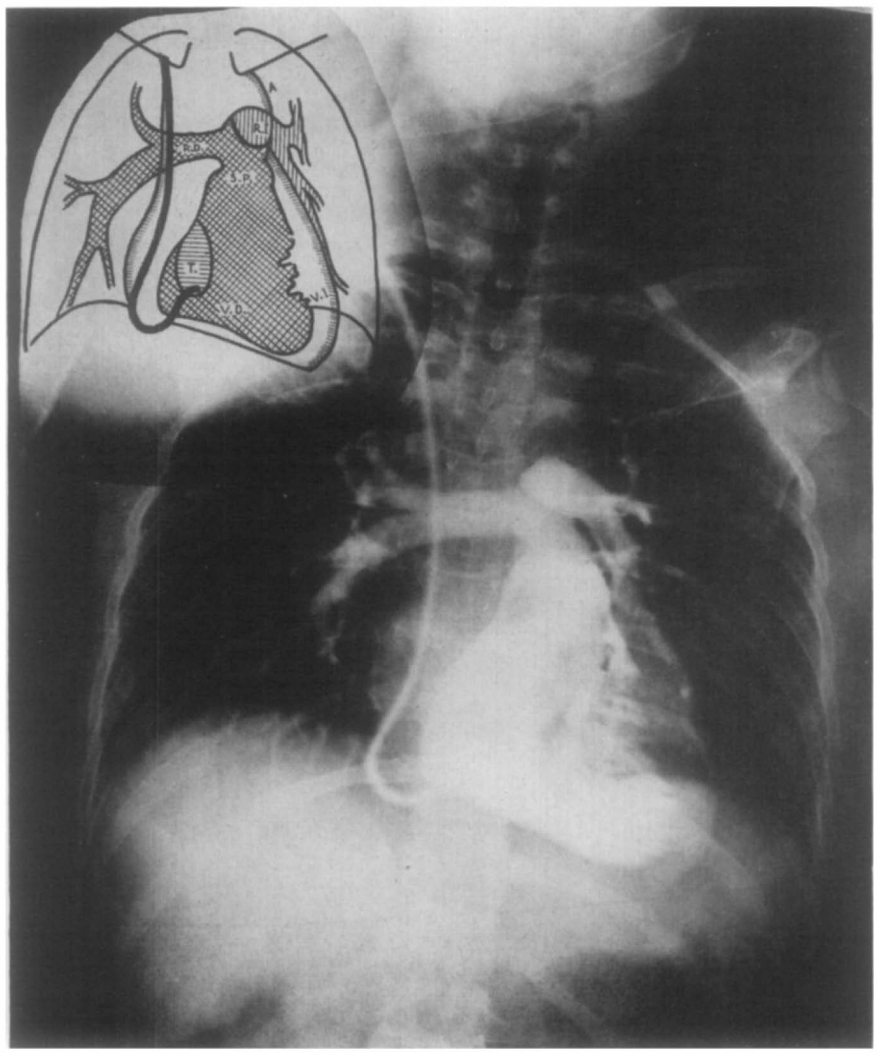

Fig. 2. Angiocardiogram of normal heart. The pulmonary artery and branches are opaquP. Relation of pulmonary artery to left border of cardiac silhouette is well shown (see tPxtL

left border as has been thought. It is only the very highest part of the left middle arc of the cardiac silhouette that is formed by the pulmonary artery proper. The left branch comes off at a right angle to the main artery. The direction

of the left branch is at first backward but the course soon becomes a downward one. It is this descending branch and not the main pulmonary artery that forms the greater part of the middle arc of the left side of the cardiac silhouette. In other words, the left middle arc is formed in a very small part by the pulmonary

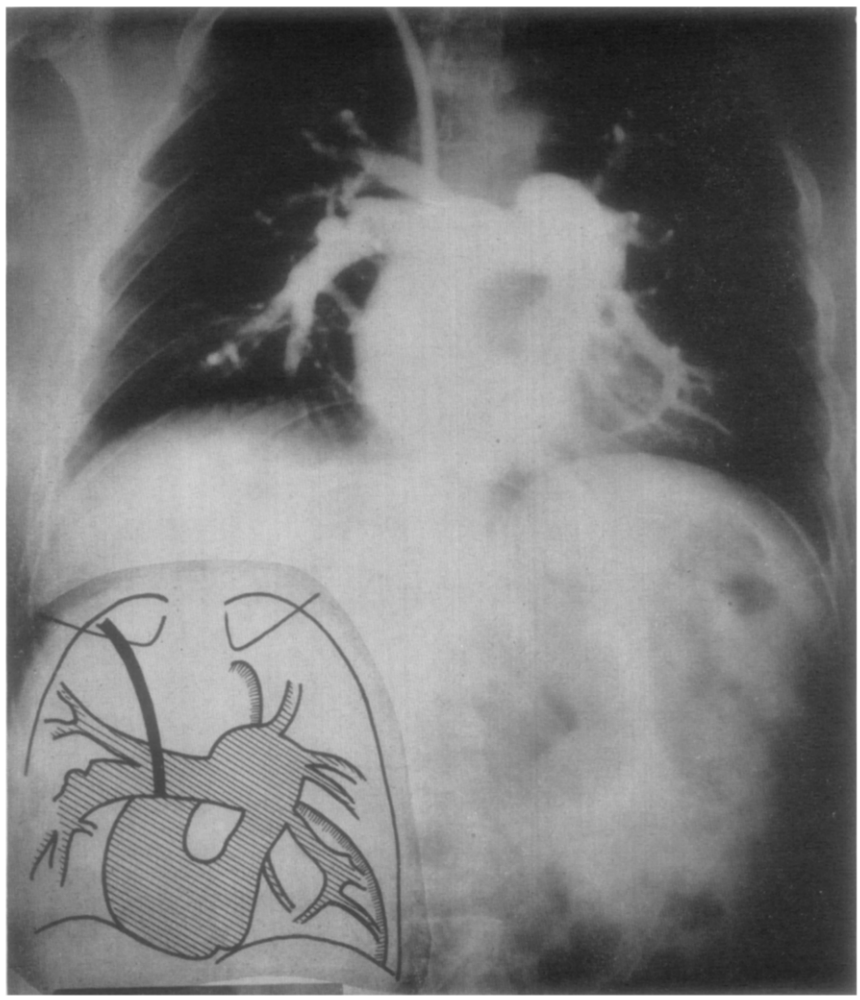

Fig. 3.—Same case as shown in Fig. 2. Pulmonary arteries and right branches are particularly shown.

artery itself; the rest is formed by the left descending branch. We have never seen the pulmonary conus placed so far to the left as to form a projection on the middle arc of the left border of the heart.

The right branch also comes off at a right angle, but its course is toward the right side of the chest. At approximately the right border of the vertebral column, it usually divides into two branches, less frequently into three. These branches spread outward rapidly. The right descendant branch is the largest. These branches are the most important shadows of the right hilum (Figs. 3, 4, and 5).

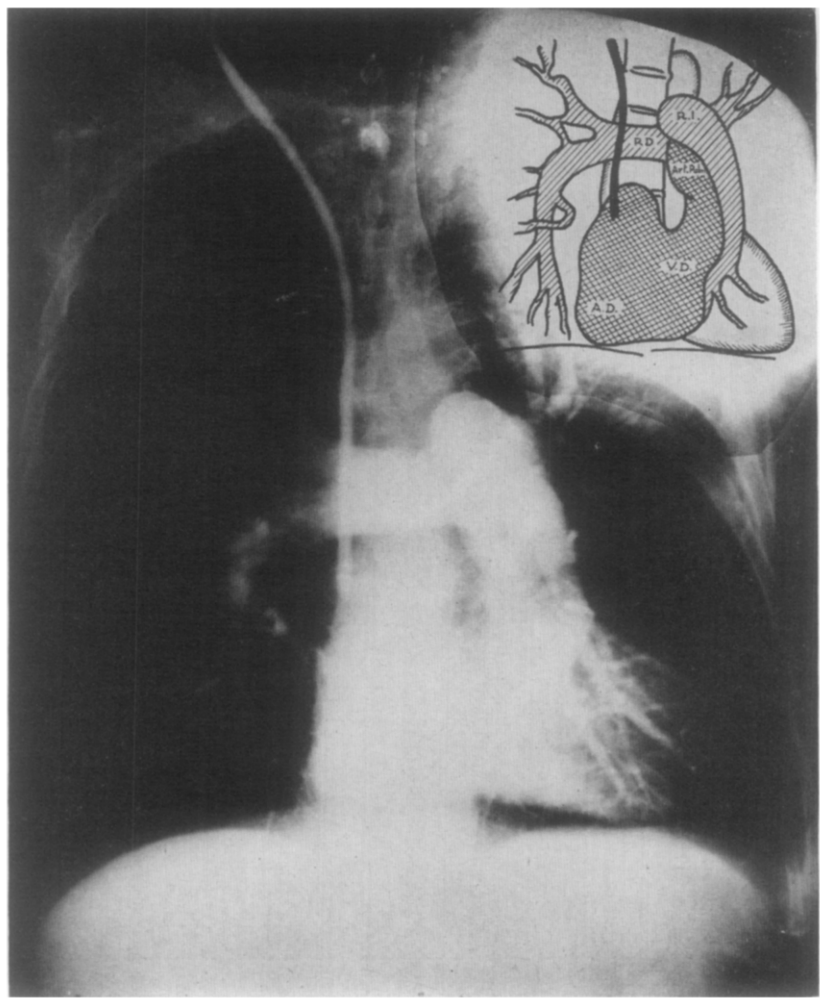

Fig. 4.—Same case as shown in Figs. 2 and 3. Pulmonary arteries and right branches are particularly shown.

We shall now describe the picture of the right heart in the lateral position (Fig. 6). In this position the superior vena cava is usually situated in the middle third of the chest. As it descends in a very gentle curve, it becomes

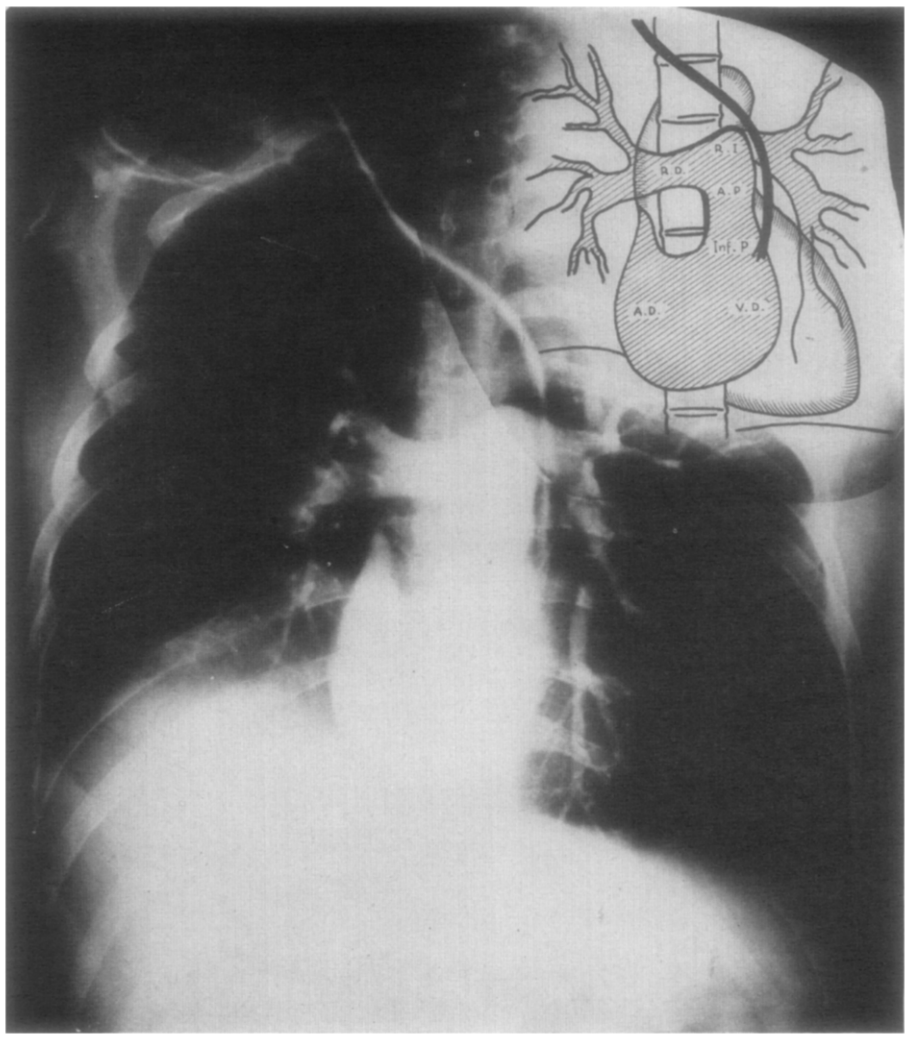

Fig. 5.—Same case as shown in Figs. 2, 3, and 4. Pulmonary arteries and right branches are particularly shown.

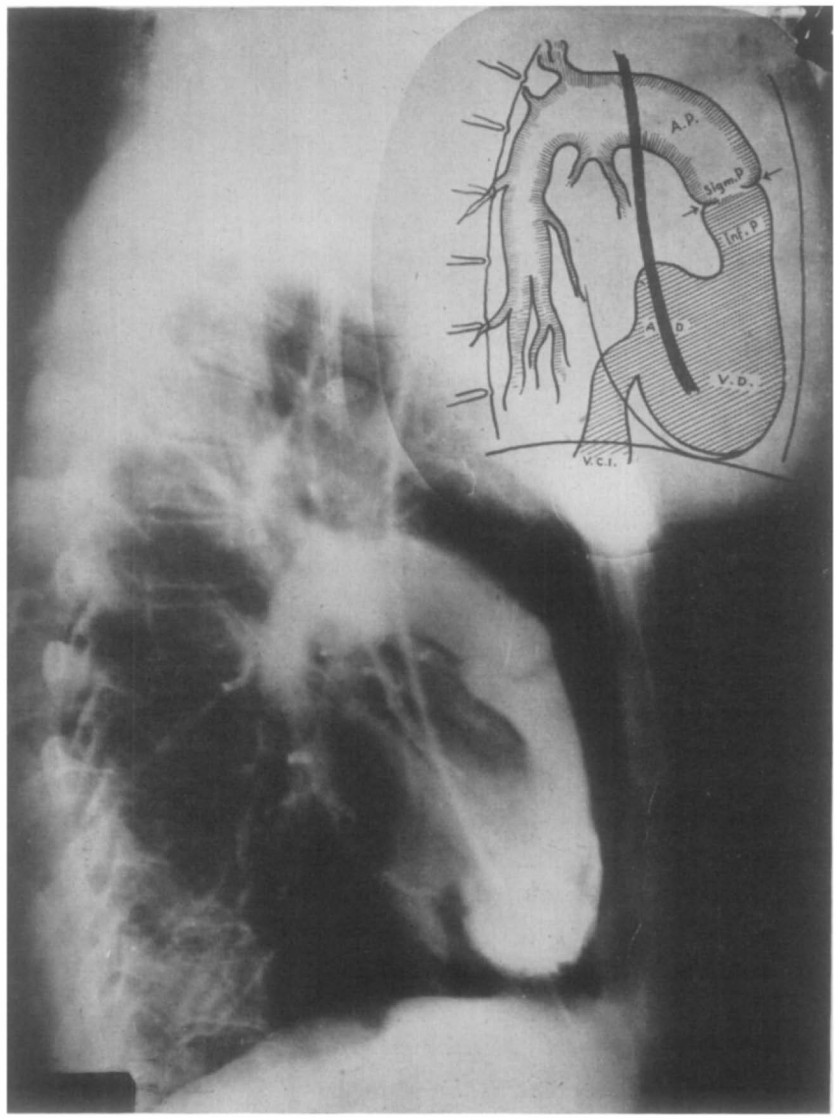

Fig. 6.--Angiocardiogram of right chambers of normal heart made in the lateral position.

widened and forms the shadow of the right atrium, which has a more or less oval shape in this projection. It is continued anteriorly by the inflow tract of the right ventricle which is visible in this projection. Ventrally there is the outflow tract of the right ventricle, which rapidly assumes an upward course

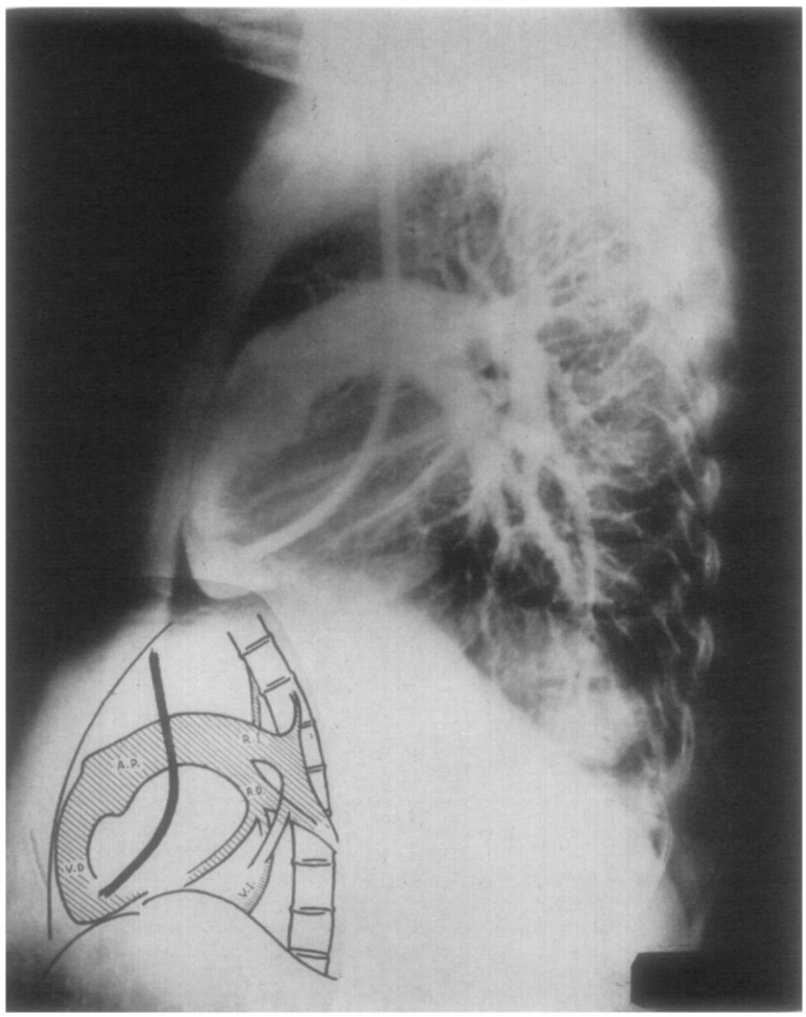

Fig. 7.—Angiocardiogram of normal right chambers and pulmonary artery. Lateral view.

until it joins the pulmonary artery itself. The diameter of the outflow tract of the right ventricle is about the same as that of the pulmonary artery. Between them, in the lateral position, are frequently seen the notches described in the frontal position, which we think are due to the pulmonary sigmoid valves (Fig. 7).

Beyond this notch the pulmonary artery takes a dorsal direction and divides into two branches, the right and left, which in turn divide into secondary branches. Quite often the opaque substance goes into the inferior vena cava (Fig. 8). The image of the injected right heart and the inferior vena cava resembles a sickle. When the opaque substance does not go as far as the inferior vena cava the image has a crescent shape. Castellanos calls this the "retort picture," since it recalls a well-known laboratory tool.

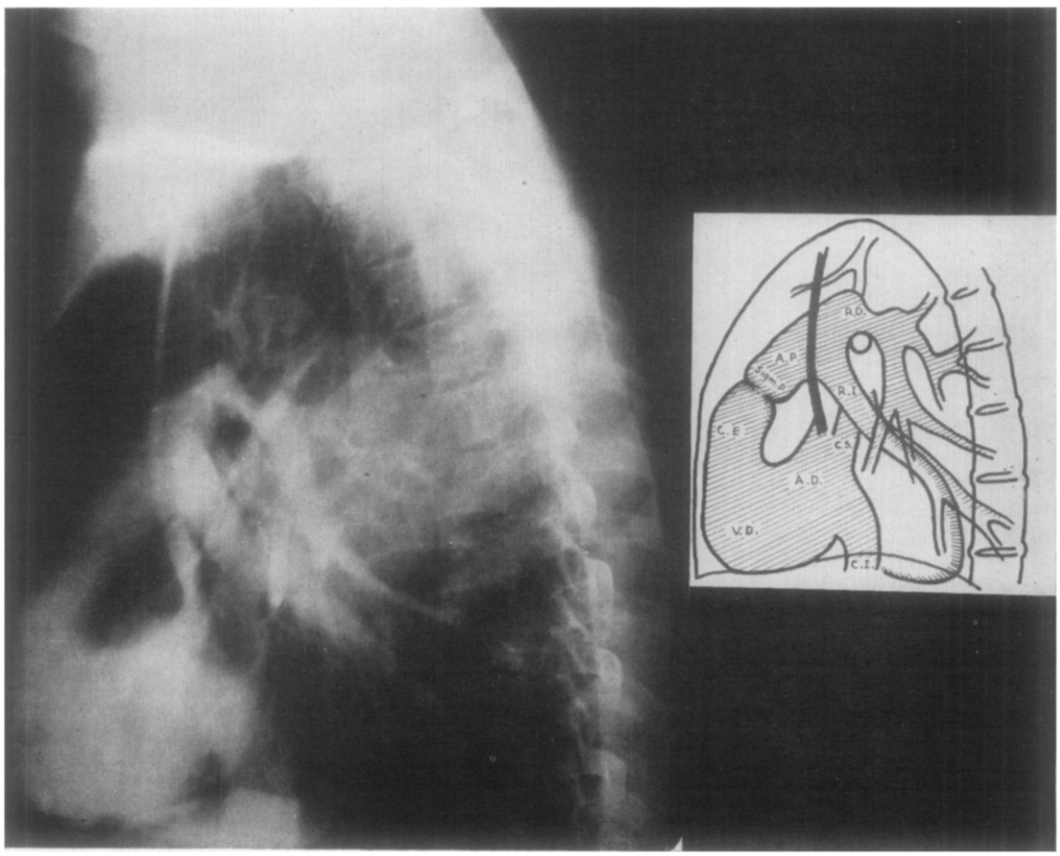

Fig. 8.—Angiocardiogram of normal right chambers and pulmonary artery. Lateral view. Note the filling of inferior vena cava.

IMAGE OF THE LEFT CAVITIES AND THE AORTA

If films are made a few seconds later, the pulmonary veins will be seen. These veins originate in the alveoli, and become more voluminous as they approach the left atrium. There are two pulmonary veins on the right side and two on the left. Two are situated cephalad, and two caudad. The left atrium soon becomes opaque (Fig. 9). Its shape resembles an "ace of spades," the apex

pointing caudad and to the left. Its shadow is superimposed on that of the vertebral column and corresponds more or less to the unfilled space of the right cavities, projecting between their limbs. Its left border is quite far from the heart's left border. The right side of the left atrium comes very near to the right

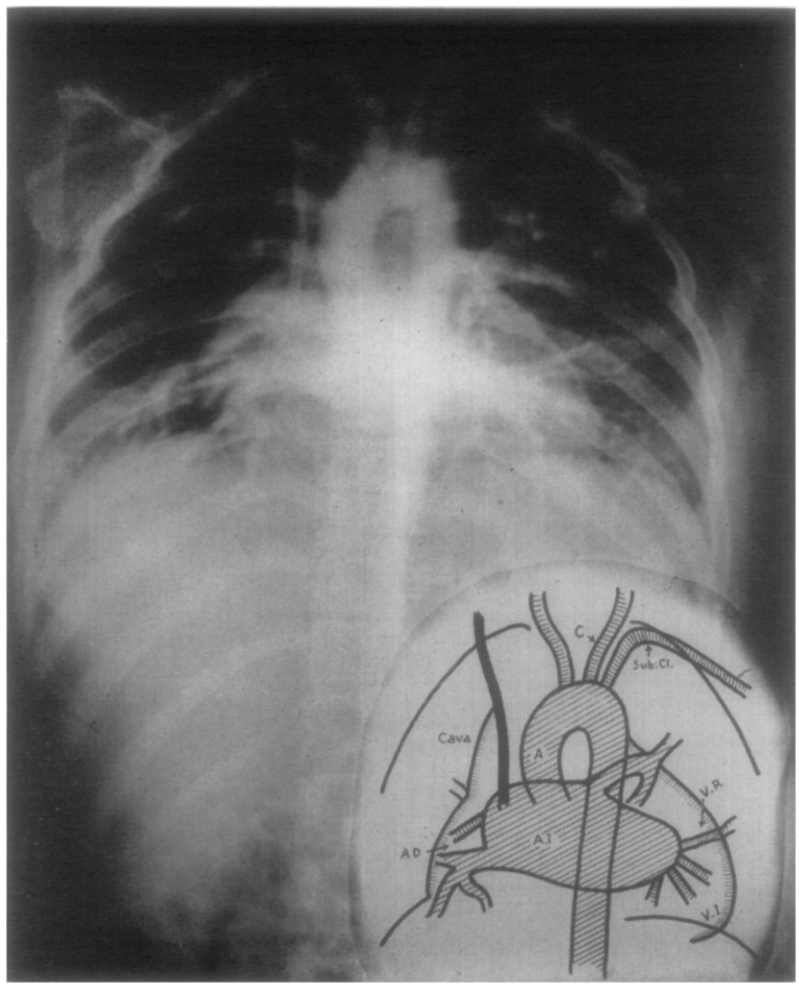

Fig. 9.—Angiocardiogram of normal left chambers. The left atrium is filled (see text).

border of the heart and very frequently the highest part of the right cardiac border is formed by the left atrium and not by the right. This fact makes it easy to understand why an enlarged left atrium frequently forms a double contour on the right side of the cardiac silhouette and why it infrequently forms a part of the left border of the cardiac silhouette. The filling of the left ventricle with the opaque substance also produces an oval shadow which is continuous

with the shadow of the left atrium, and extends as far as the apex of the heart. It is very common to see a deep notch between the left atrium and the ventricle. If we consider the picture of the atrium and the ventricle together they resemble roughly a figure eight.

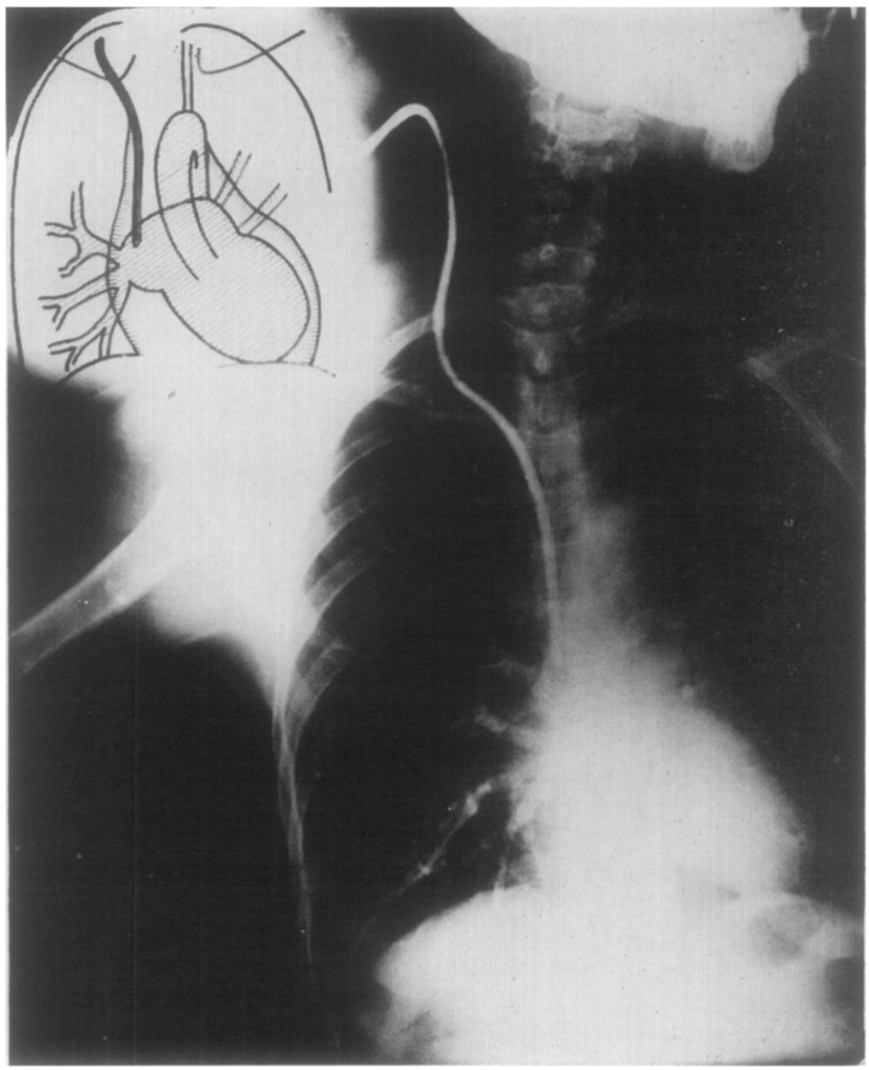

Fig. 10.—Angiocardiogram made in systole (see text).

This picture is obtained when we catch the heart in diastole but it varies when the film is made during systole. In the latter case the aorta is completely filled; there is no filling of the left ventricle and usually, but not always, there remains some radiopaque substance in the left atrium. We have already pointed

out that the right ventricle is always visible, though its shape will vary in films taken during diastole and systole. The left ventricle usually empties completely during systole. A film made in systole will show the aorta to be completely filled but the left ventricle will not be visualized, unless there is some pathologic circumstance which causes part of the substance to be retained (Fig. 10).

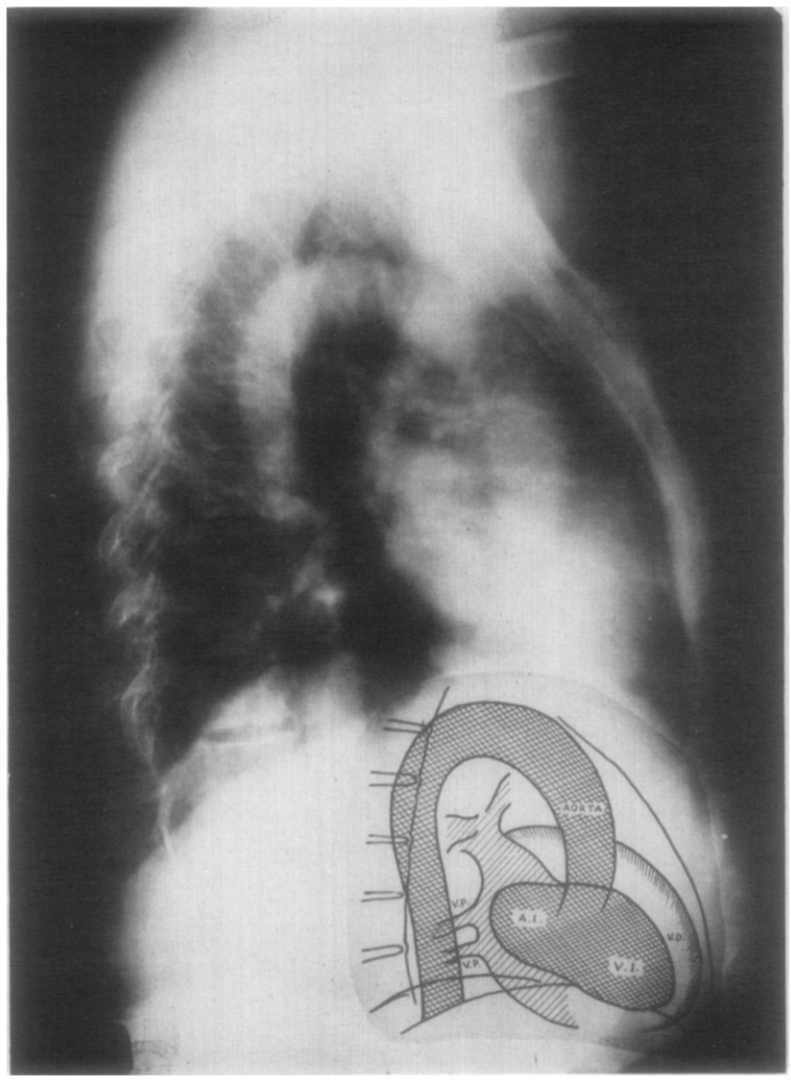

Fig. 11.—Angiocardiogram made in the lateral position. In this position the left chambers are not well visualized; the aorta and the pulmonary arteries are well visualized.

The complete filling of the left ventricle makes it possible to appreciate the location of the interventricular septum and in many cases the thickness of the ventricle wall. On the other hand, the inflow and the outflow tracts of the left

ventricle cannot be differentiated as they can be in the right ventricle; there is no demarcation between them.

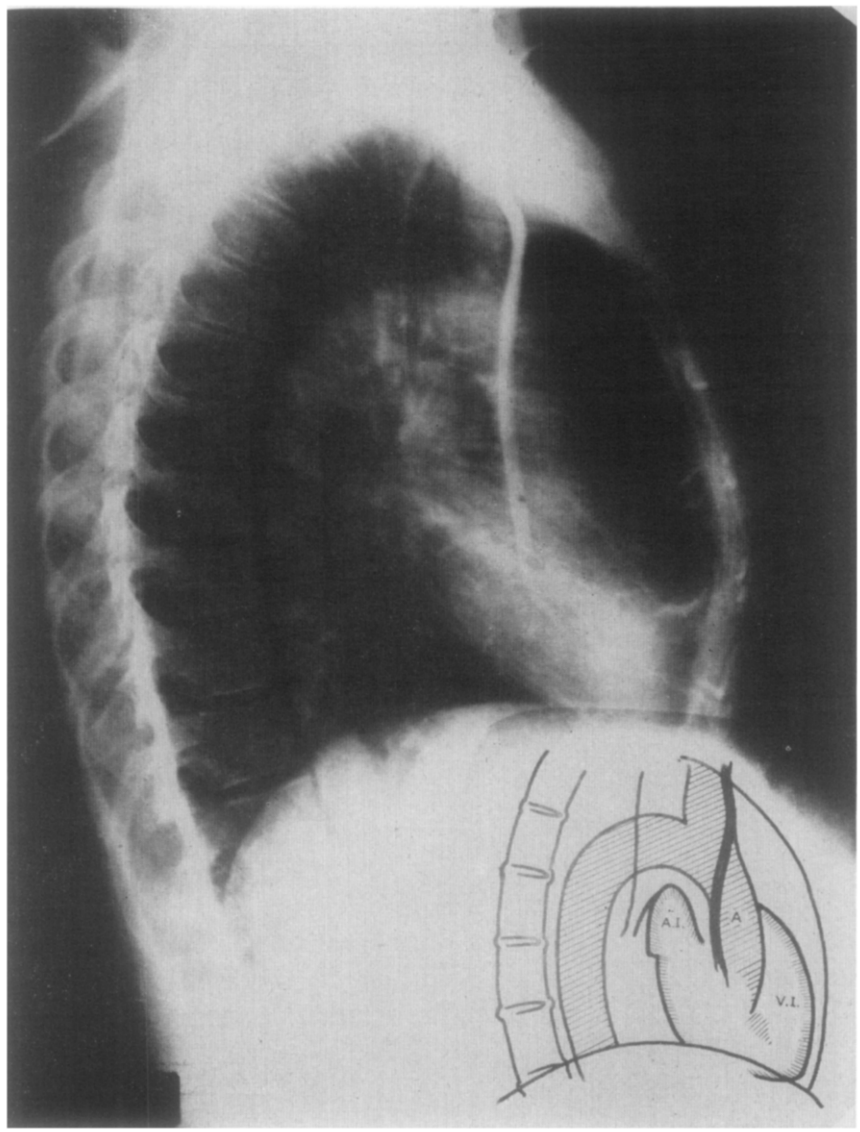

Fig. 12.—Angiocardiogram of normal left chambers made in the lateral position. A notch marking the position of the aortic valves and a dilatation indicating the position of the sinuses of Valsalva are often seen (see text).

In the same anteroposterior projection the aorta is well visualized. It usually leaves the left ventricle at the level of the projection of the left border of the vertebral column. When the left ventricle is empty and the left atrium

still contains radiopaque substance, the aorta appears to come out from the left border of the atrium. Then it ascends more or less rapidly, depending on the shape of the heart, and then turns downward. The full descending aorta, the innominate artery, the two main carotids, and, lower down, sometimes the intercostal arteries can be visualized. Occasionally the completely filled renal arteries are seen.

The lateral projection (Fig. 11) is not very useful for visualizing the left chambers but it is useful for visualizing the pulmonary artery and the aorta; these structures are better seen in this position than in any other. The chambers of the left heart in this position are small. In the lateral projection the left chambers as a whole also resemble a figure eight. The aorta can be seen coming out from the left ventricle at about the upper loop of the figure eight; it rapidly ascends and is quite near the anterior chest wall. At this point an anterior and a posterior notch very similar to those seen in the pulmonary artery can be seen (Fig. 12). Immediately above the notch there is a slight dilatation. We think that the notch is due to the sigmoid valves and the dilatation to the sinuses of Valsalva. The situation of the aorta naturally varies according to the shape of the chest and to the age of the subject: in older people it is not so near the chest wall.

ABNORMAL IMAGES

In order to clar description and to facilitate comparison with the normal images, we shall describe the pathologic images which will be described in the same order that has been used in describing normal hearts. The structures

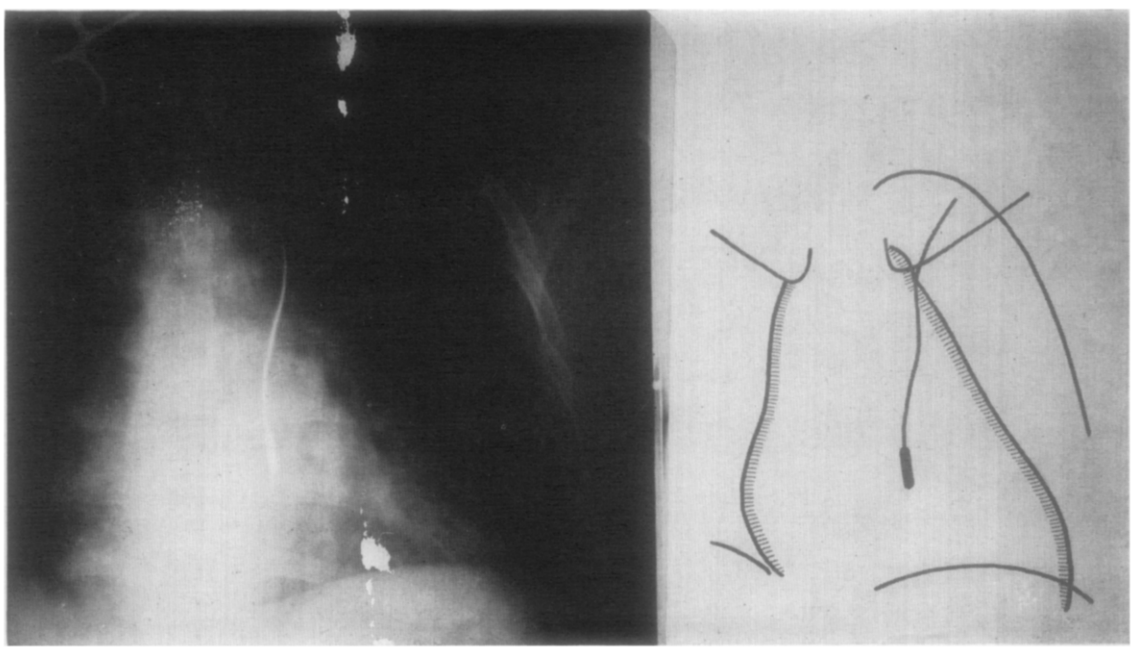

Fig. 13.—Angiocardiogram of a patient with persistent left superior vena cava.

and chambers will be discussed in the order on which they are visualized after the injection of the opaque substance. Two main contingencies may be present: (1) the substance may follow the normal circuit; or (2) it may follow an anomalous course, because of perforations of the septa, or the vessels do not have normal origins or connections, or there are abnormal communications between the vessels.

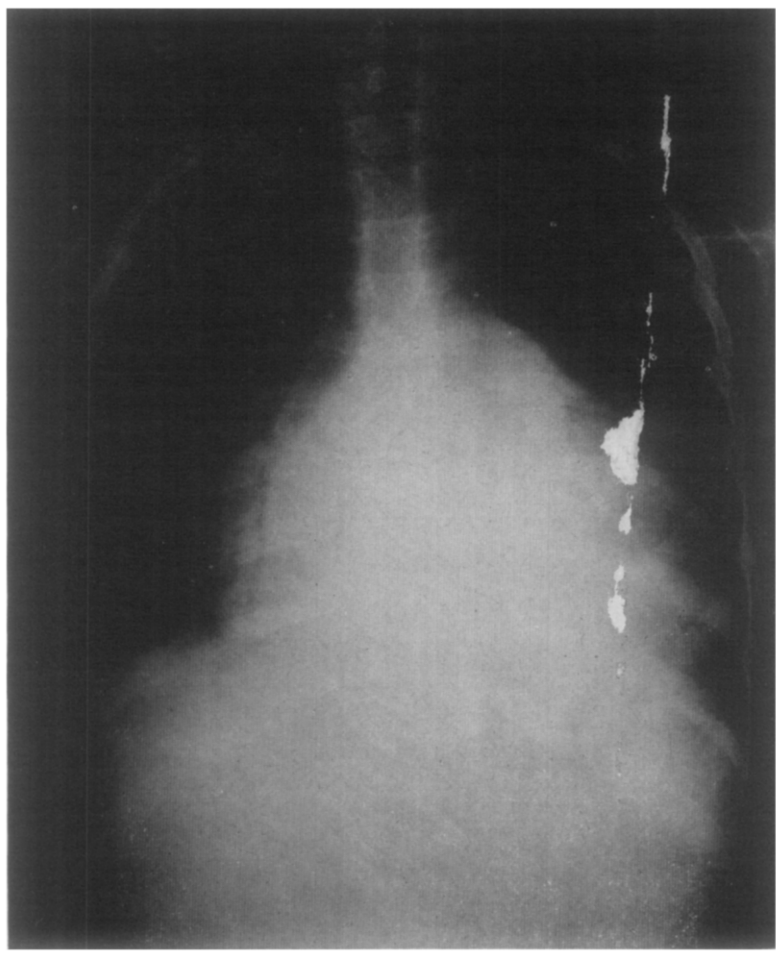

Fig. 14.—Ordinary x-ray film of patient with mitral and tricuspid stenosis.

Abnormal Images With Normal Routes of Flow.—The image of the *superior vena cava* is always perceptible. In most instances the injecting catheter is inserted into this vessel. Even when it is not possible to catheterize it, and when the injection has to be made into the jugular vein with a large-guage needle, the presence of the opaque substance makes possible the identification of the vena cava and the recognition of anomalies of this vessel. Fig. 13 shows a persistent left superior vena cava which is probably connected directly to the left

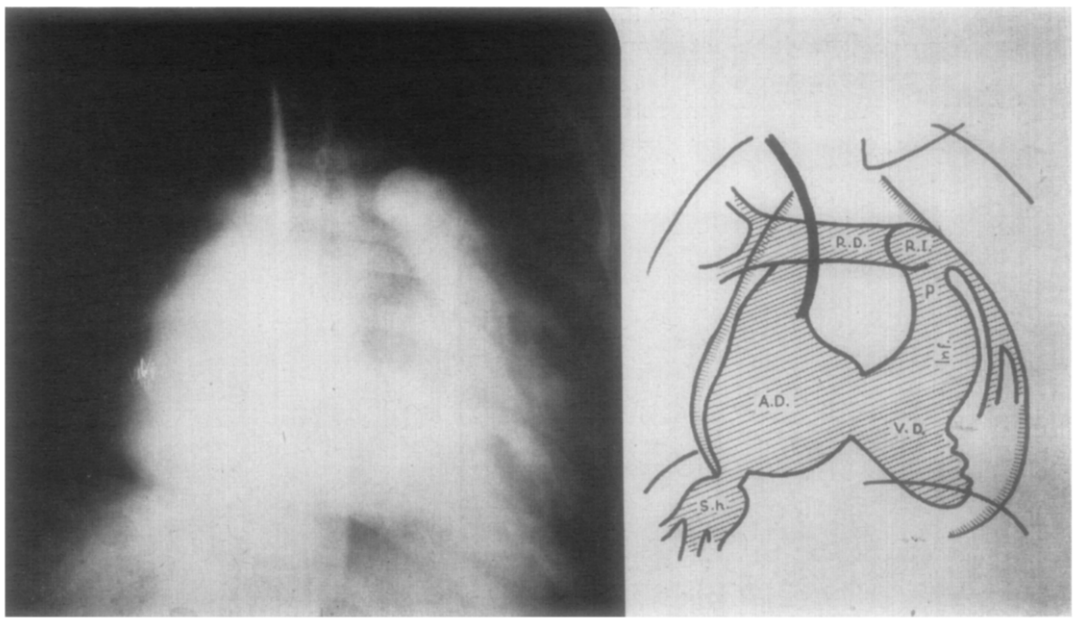

Fig. 15.—Angiocardiogram of same case shown in Fig. 14 (see text).

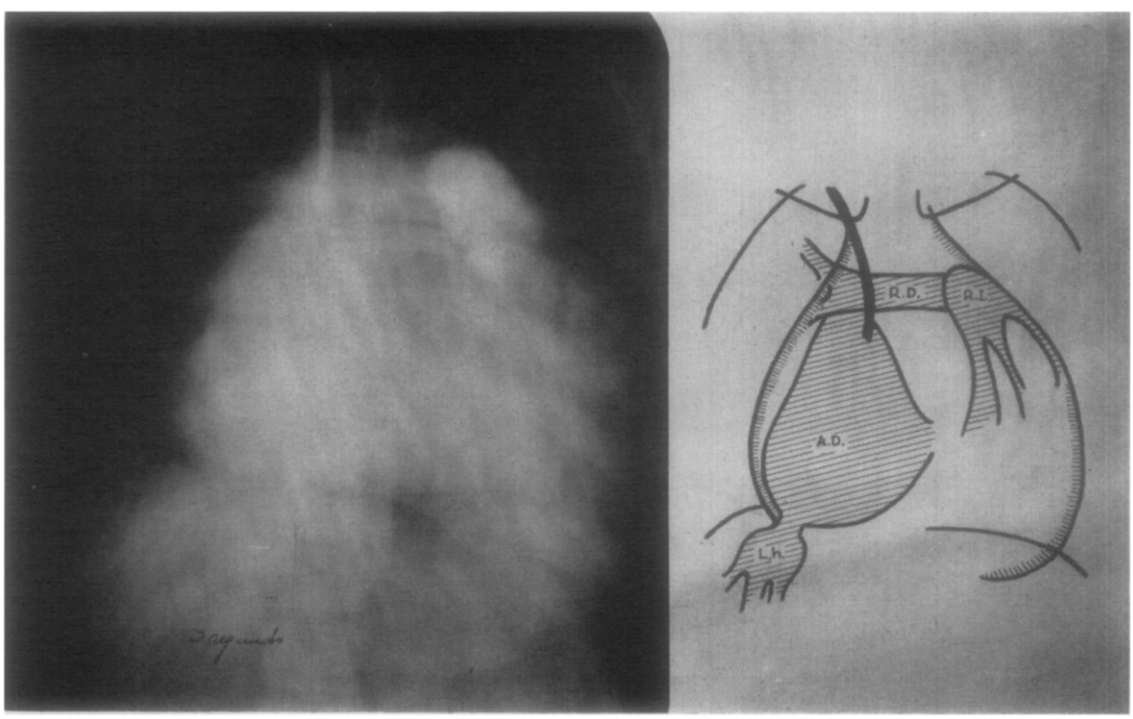

Fig. 16.—Angiocardiogram of same case shown in Figs. 14 and 15 (see text).

auricle. The electrocardiogram that was recorded indicated that the catheter which contained the electrode probably entered the right ventricle.

The *right auricle* is seldom seen as an isolated chamber. Since it empties promptly into the ventricle, the image obtained usually shows both cavities together. It is possible to see the auricle alone, however, when the ventricle empties and the auricle remains full; this is often the case in tricuspid stenosis, (Fig. 14). Here is an ordinary x-ray of a patient with rheumatic mitral disease and with a marked dilatation of the cavities. The angiocardiogram (Fig. 15)

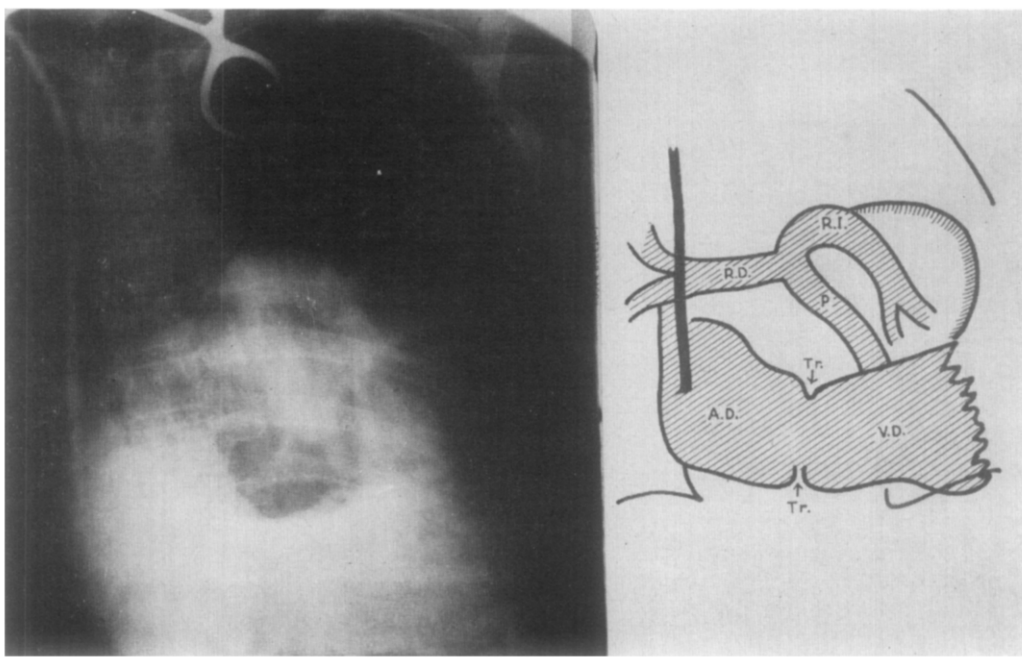

Fig. 17.—Angiocardiogram of a patient with an aortic aneurysm which compressed the infundibulum of the pulmonary arteries. A notch caused by the tricuspid valve is seen.

at the end of the injection shows an enormous right auricle, clearly separated from the ventricle by a narrow zone corresponding to the tricuspid valve. In Fig. 15, however, the right ventricle is full, as well as the two branches of the pulmonary artery; but three seconds later, (Fig. 16), the ventricle has emptied while the auricle still retains the opaque substance: it remained full six and even ten seconds after the injection, when the aorta was already completely visible. The diagnosis of tricuspid stenosis in this case had escaped the clinical examination.

The image of the *right ventricle* may be missing or it may be greater than normal or, finally, it may show deformations. We shall discuss later the cases where it is not seen, since they depend upon complex malformations. Fig. 17 is a good example of an exaggerated enlargement of this cavity; it is prolonged

as far as the apex and reaches the left border of the heart, in contrast to a narrow and elongated expulsion chamber. The left branch of the pulmonary artery is clearly visible. This film was obtained from a patient with an aortic aneurism which compressed the region of the pulmonary infundibulum. In this same plate the notch marking the site of the tricuspid valve is seen. To the best of our knowledge this is the first time that this structure has been visualized.

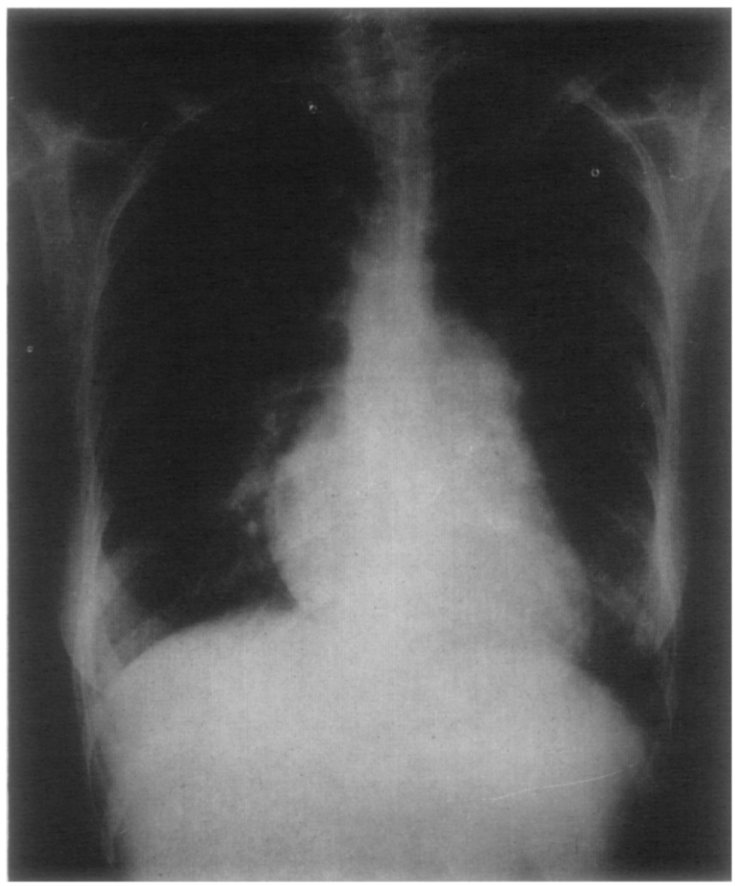

Fig. 18.—An ordinary x-ray film of a patient with mitral stenosis.

We have also found this image of dilatation of the main *trunk of the pulmonary artery* and of its branches, and diminished size of the infundibulum in the course of rheumatic mitral stenosis, with no clinical sign to make us suppose that there was either a narrowing or a compression of the infundibulum. Fig. 18 corresponds to an ordinary mitral silhouette. The patient had a classical stenosing valvulitis. The protuberance whch deforms the medial arc makes us suspect that there is a greatly dilated left pulmonary branch. Actually, three seconds after the injection (Fig. 19), the trunk of the artery and its left branch are seen to be very

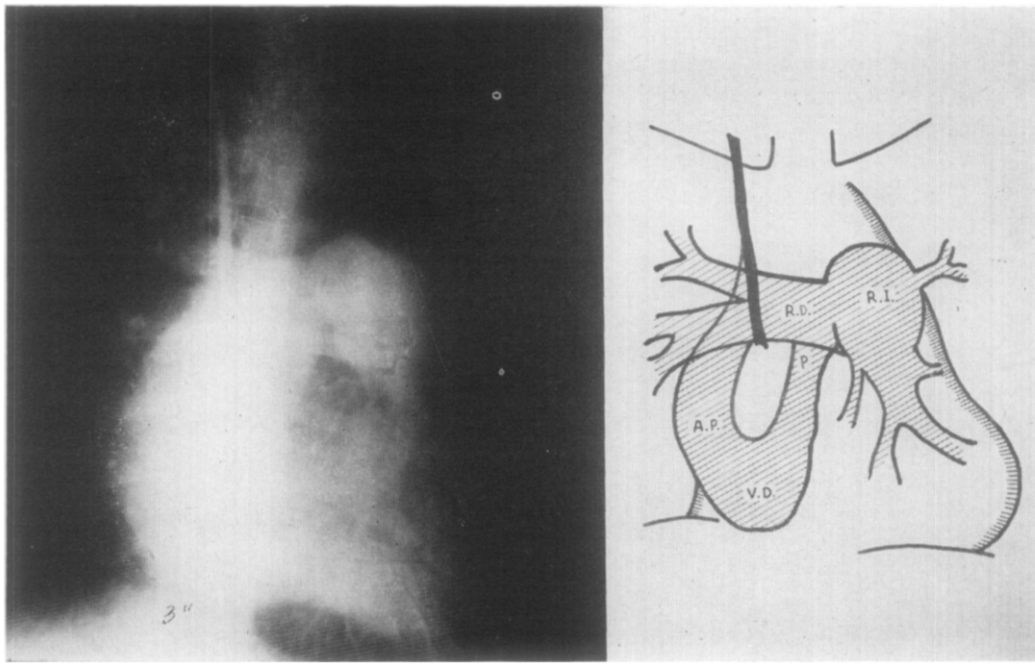

Fig. 19.—Angiocardiogram of same case shown in Fig. 18 (see text).

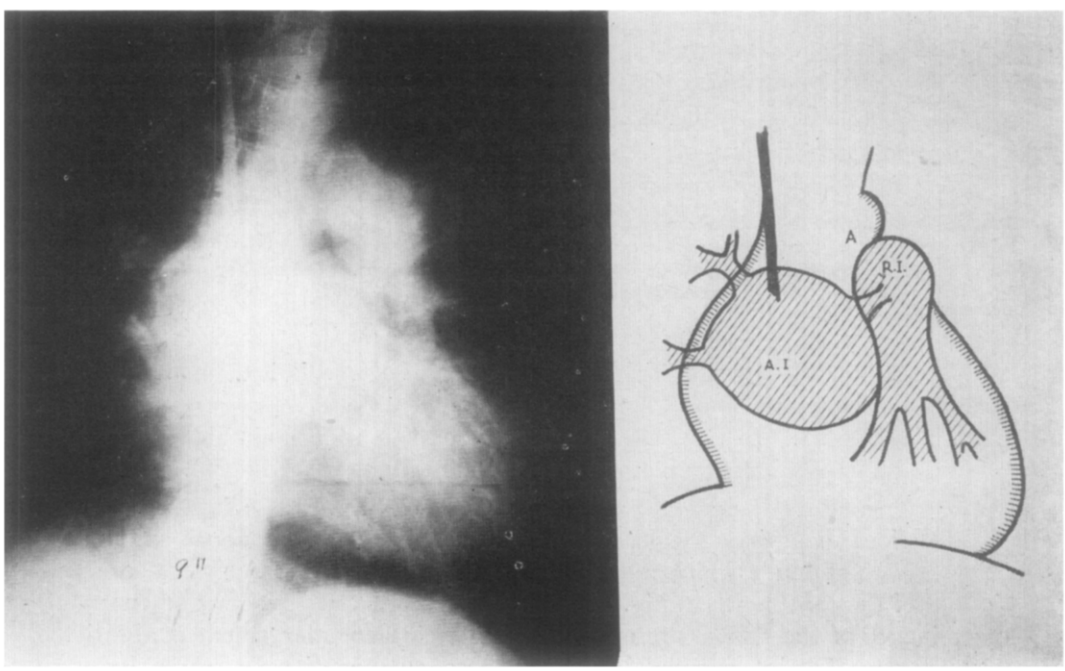

Fig. 20.—Angiocardiogram of same case shown in Figs. 18 and 19 (see text).

dilated. The infundibulum, on the other hand, can not be seen. Six seconds after the injection, the pulmonary and infundibular images are similar, and even three seconds later the arteries are still opaque (Fig. 20), although the left auricle is full. This plate provides a beautiful visualization of the isolated *left auricle*, only slightly enlarged but with a clear lower limit which corresponds to the mitral valve.

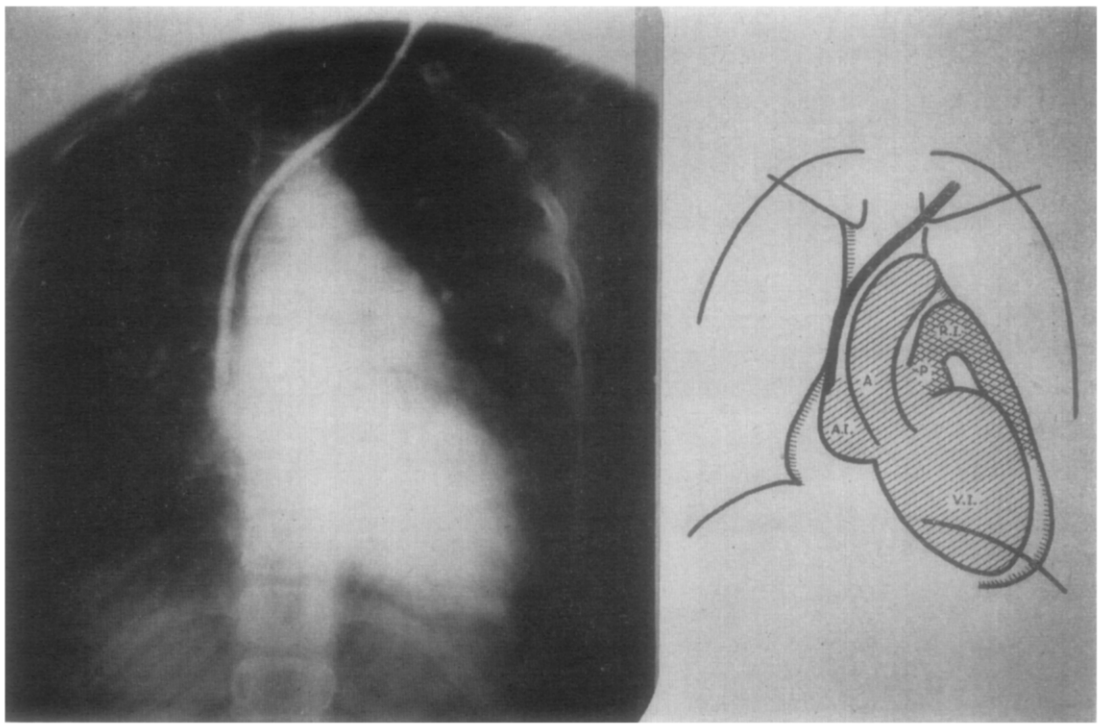

Fig. 21.—Angiocardiogram of patient with patent ductus arteriosus. The opacity of the pulmonary artery is maintained until the aorta is filled.

Regarding the left cavities, the most common occurrence is to find both chambers full at the same time. A marked enlargement of the *left ventricle* is clearly shown in Fig. 21. In this case an undiagnosed condition maintained the filling of the pulmonary artery up to the time of the filling of the aorta. This fact, as we shall see later, strongly suggests a persistence of the ductus arteriosus.

Angiocardiography yields very beautiful plates of the aorta and allows diagnosis to be made which may not be reached otherwise. A typical example is that of the case shown in Fig. 22, a simple x-ray film which shows an enormous prominence of the medial arc and a moderate cardiac enlargement of the right-sided type. The image strongly suggests an aneurysm, either of the pulmonary artery or of the aorta at the sinus of Valsalva. The clinical problem was not

easy. The patient, a 45-year-old man, had syphilis. The precordial region bulged slightly at its base, and there was a double beat. A slight systolic murmur and a somewhat louder diastolic murmur could be heard in the third left intercostal space. The radial pulse, however, was not of the collapsing type. Furthermore, the enlargement was of the right and not of the left cavities. The injection

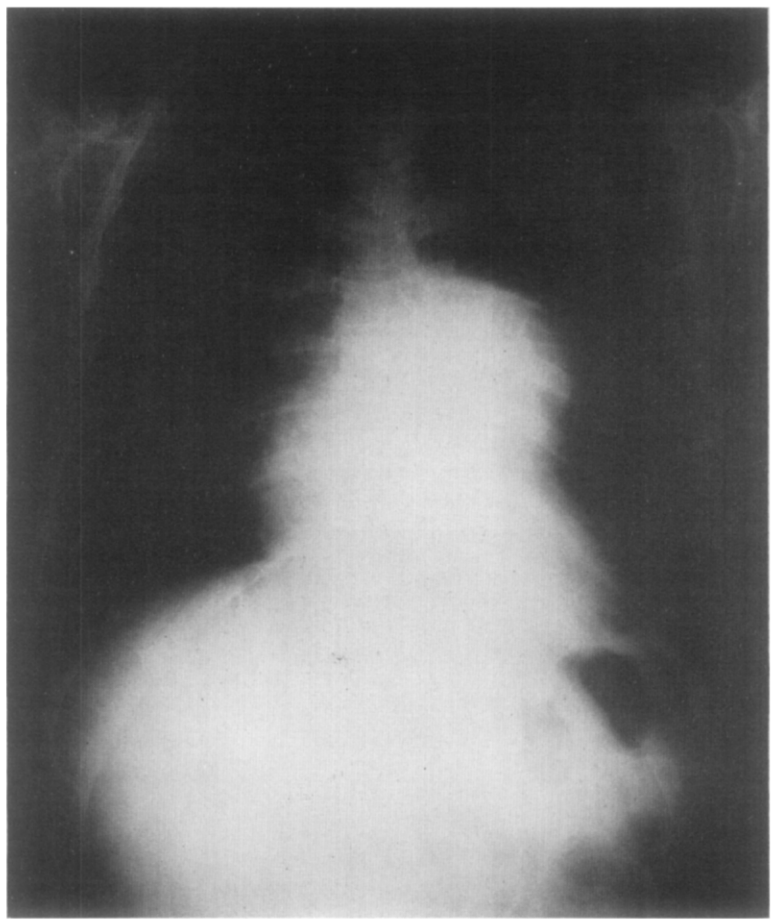

Fig. 22.—An ordinary x-ray film of a patient with an aneurysm of the left sinus of Valsalva which compressed the pulmonary infundibulum.

of opaque substance eliminated all doubts, (Fig. 23). At its end, the right cavities and the pulmonary artery with its branches were filled. The bulge, however, had not changed. The right cavities were clearly dilated and did not empty, either in four or in eight seconds, thus demonstrating the presence of an obstruction. When after twelve seconds they did empty (Fig. 24), the left ventricle and also the aneurysmal pocket and the descendent aorta were seen to

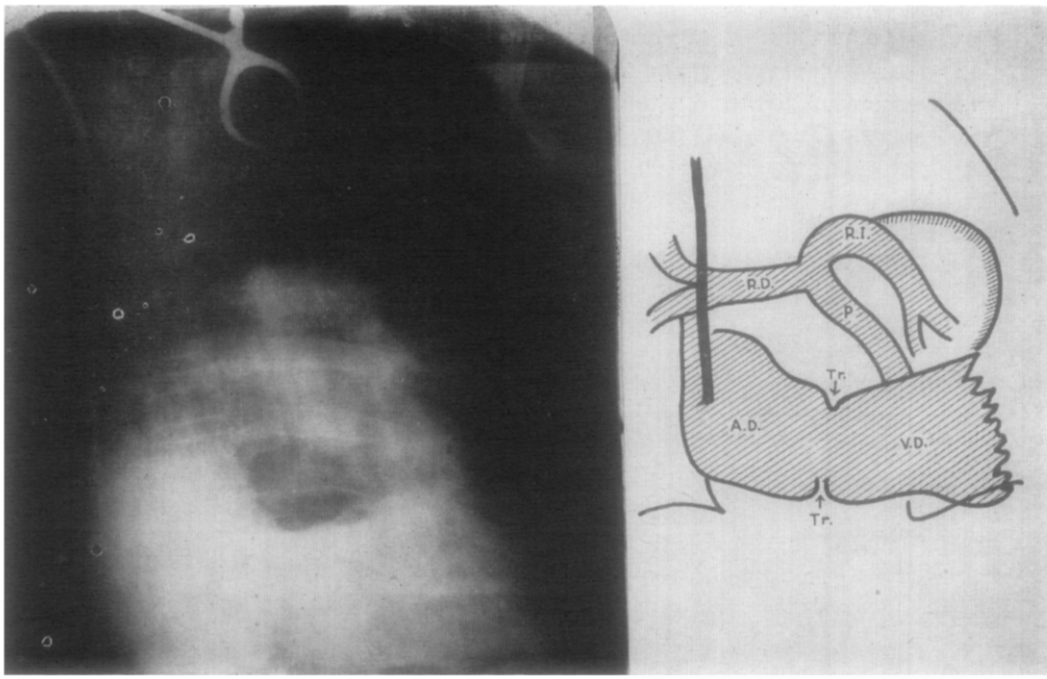

Fig. 23.—Angiocardiogram of same case shown in Fig. 22 (see text).

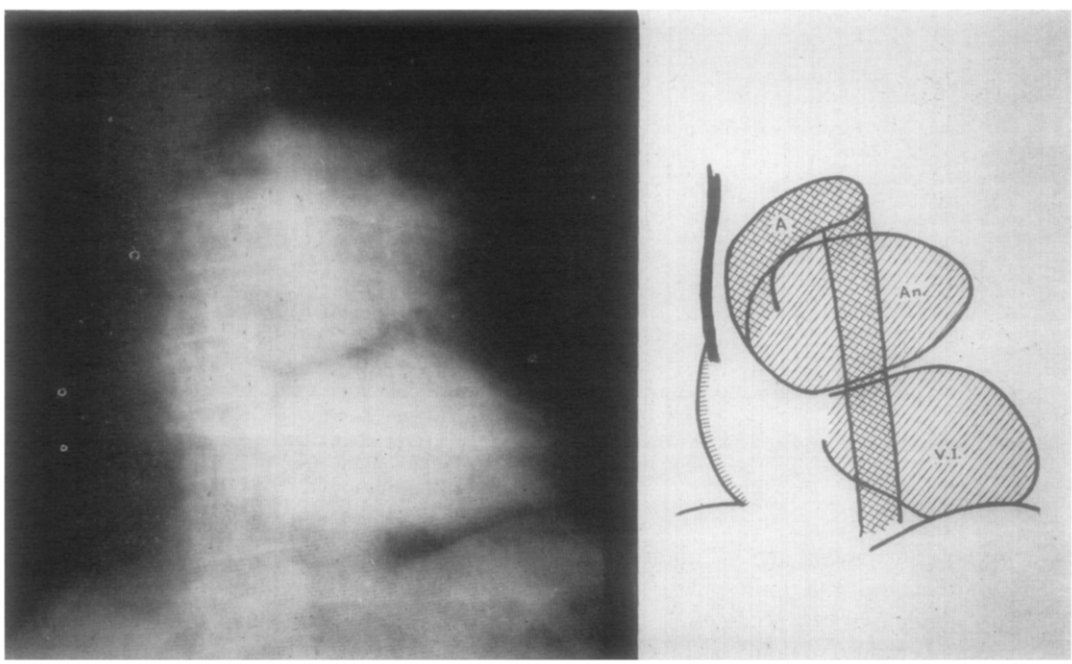

Fig. 24.—Angiocardiogram of same case shown in Figs. 22 and 23 (see text).

be filled. The diagnosis of *aortic aneurysm* of the left sinus of Valsalva with compression of the pulmonary infundibulum could be established with certainty.*

Not less interesting is the contribution of the method to cases of *isthmic stenosis* or *coarctation of the aorta.* In the ordinary x-ray film (Fig. 26), taken with a Bucky diaphragm and at a short distance in order to demonstrate Roesler's

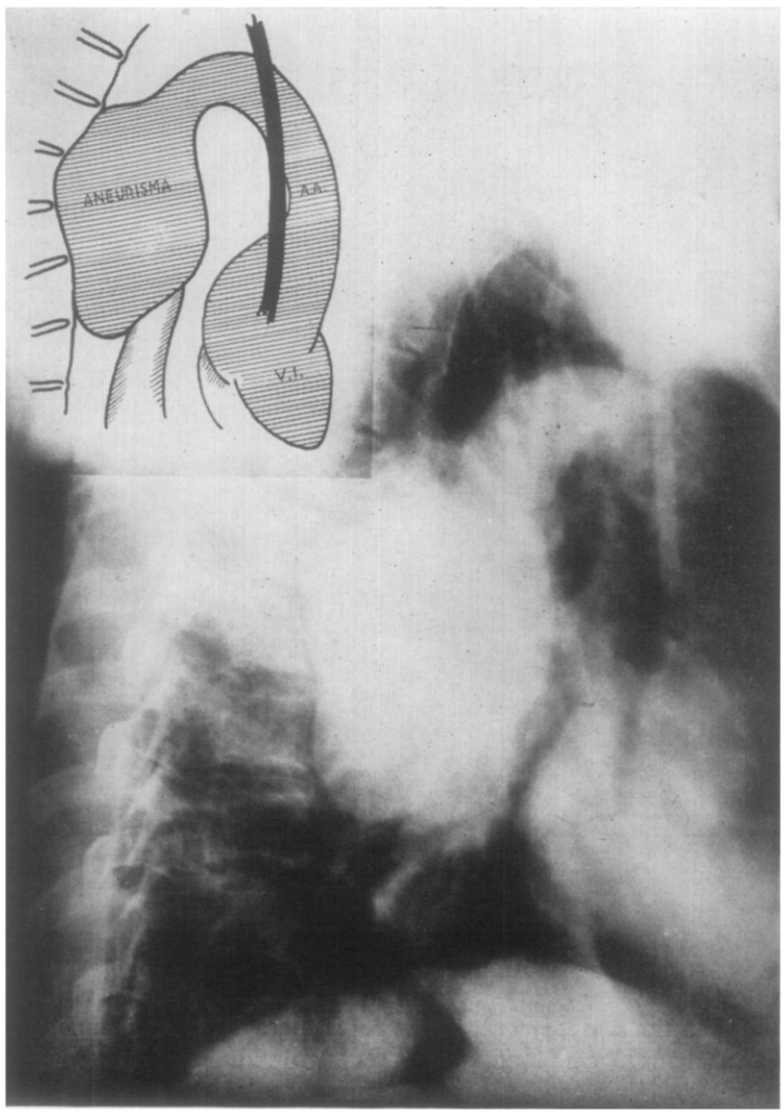

Fig. 25.—Angiocardiogram of a patient with a huge aneurysm of the thoracic aorta.

*In another type of aortic aneurysm the differential diagnosis from tumors can be established with precision. Fig. 25 shows a huge aneurysm of the thoracic aorta. It would be very difficult to demonstrate this by any other means.

sign of costal erosion, a quasi-normal cardio-aortic silhouette is seen with only slight enlargement of the left ventricle (confirmed later by a teleroentgenogram). In the lateral position at the end of an injection (Fig. 27) a splendid normal image of the right cavities and of the pulmonary branches is seen. Four seconds later (Fig. 28), on the other hand, the left cavities likewise appear normal, except for a thick ventricular wall. The ascending aorta and the transverse and initial portion of the descending aorta are all filled with the opaque sub-

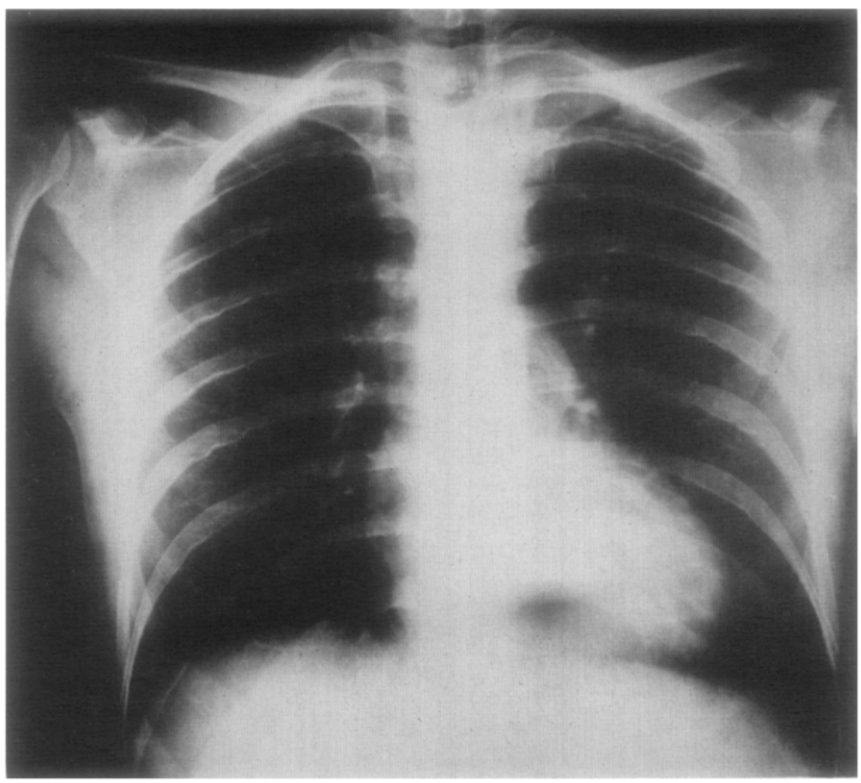

Fig. 26.—An ordinary x-ray film of a patient with a coarctation of the aorta.

stance up to the level of the intersection with the pulmonary artery. The six-second plate (Fig. 29) still shows a visible aortic arch and, also, a visible thoracic aorta. Between the two segments of the aorta there is a narrow zone, practically invisible and about 3 cm. long, where the two visualized segments approach each other by slender elongated tips. The narrowing is particularly noticeable in the image of the thoracic aorta, whose upper part is needlelike, and is followed immediately by a spindle-shaped dilatation about 6 cm. long, continued below by a narrow, hypoplasic aorta, which strongly contrasts with the wide ascending aorta.

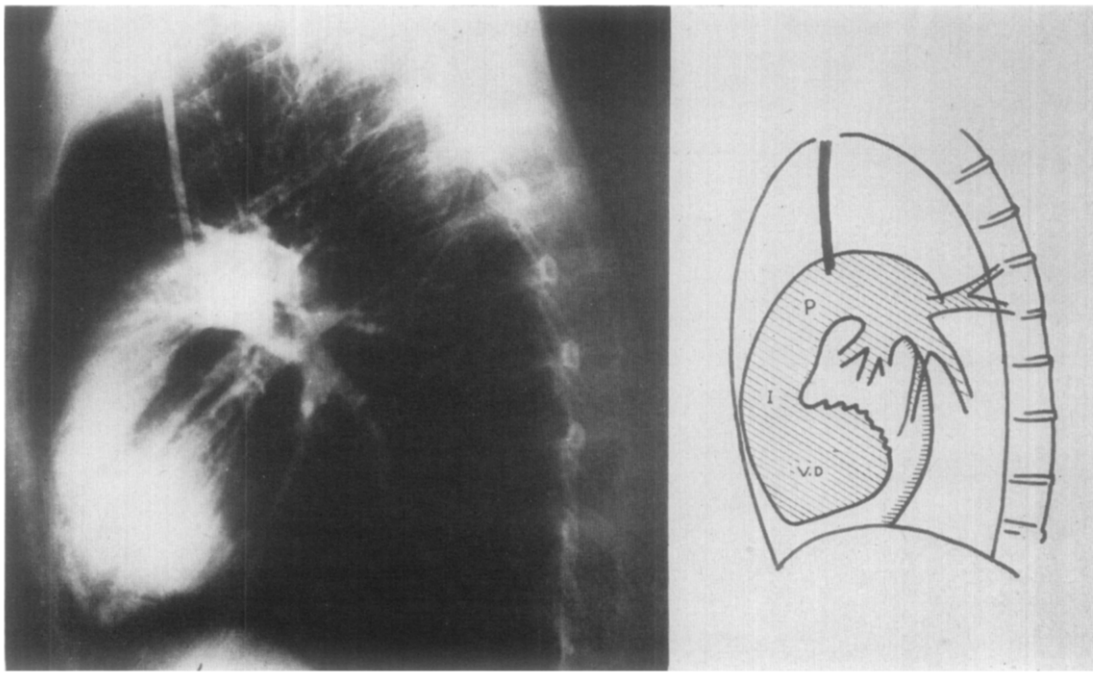

Fig. 27.—Angiocardiogram of same case shown in Fig. 26 (see text).

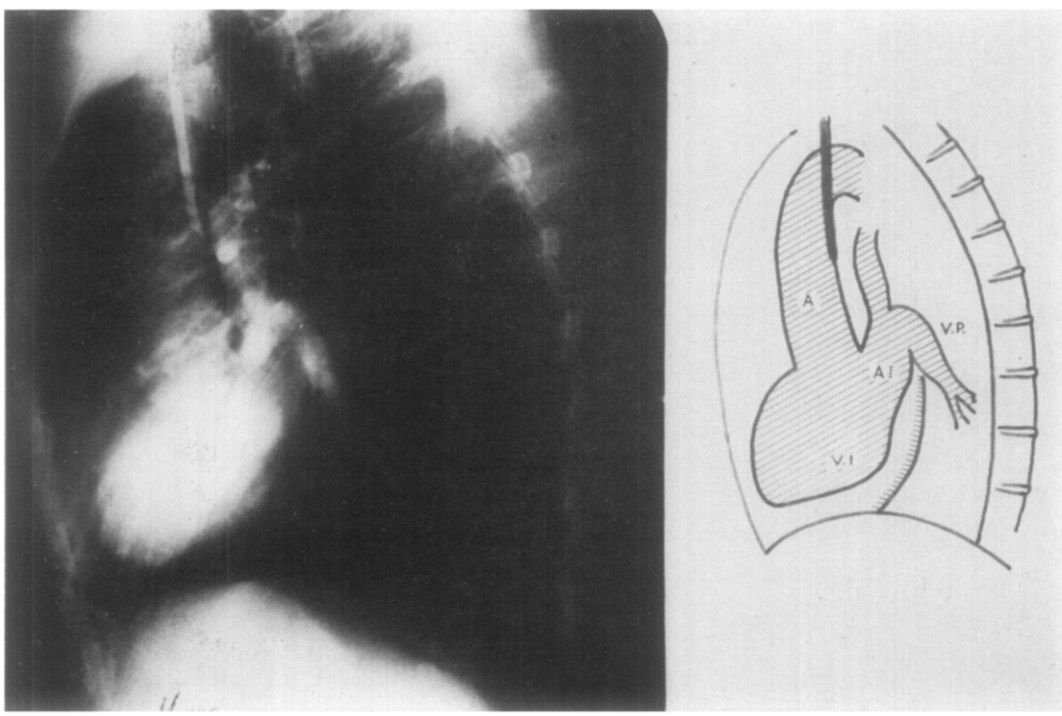

Fig. 28.—Angiocardiogram of same case shown in Figs. 26 and 27 (see text).

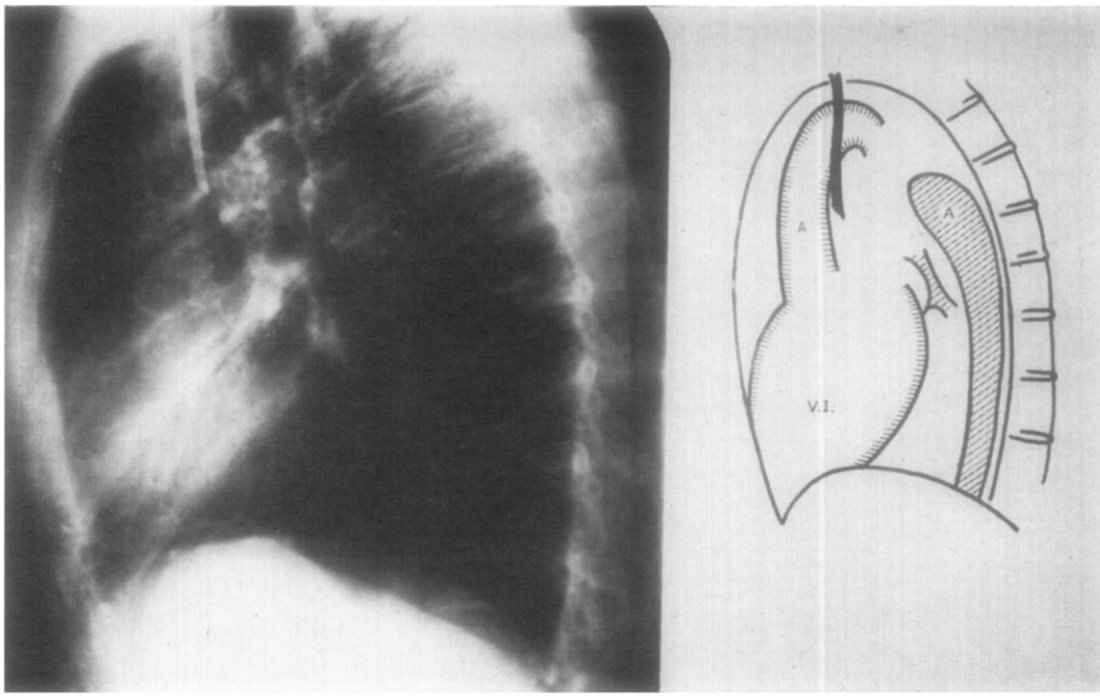

Fig. 29.—Angiocardiogram of same case shown in Figs. 26, 27, and 28 (see text).

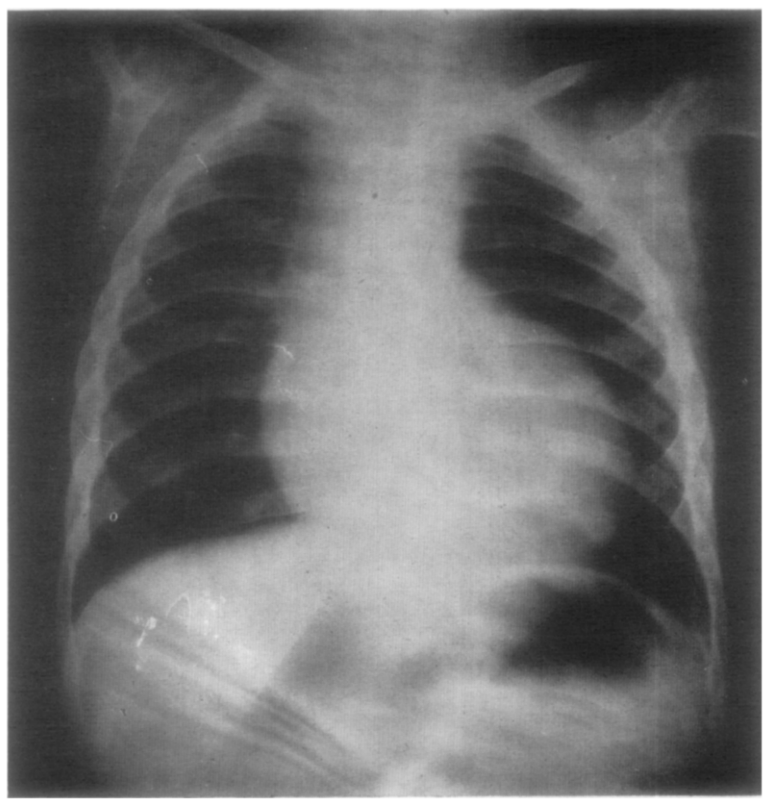

Fig. 30.—An ordinary x-ray film of a 4-year-old child with cor biloculare or cor triloculare biatriatum with a persistence of a single arterial trunk.

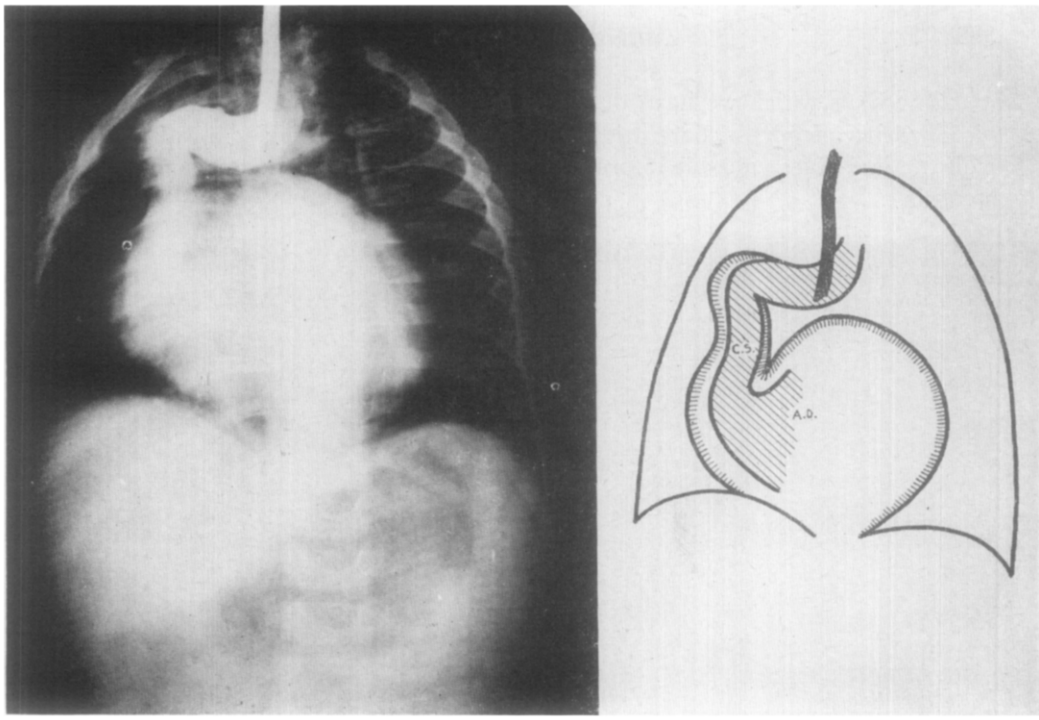

Fig. 31.—Angiocardiogram of same case shown in Fig. 30 (see text).

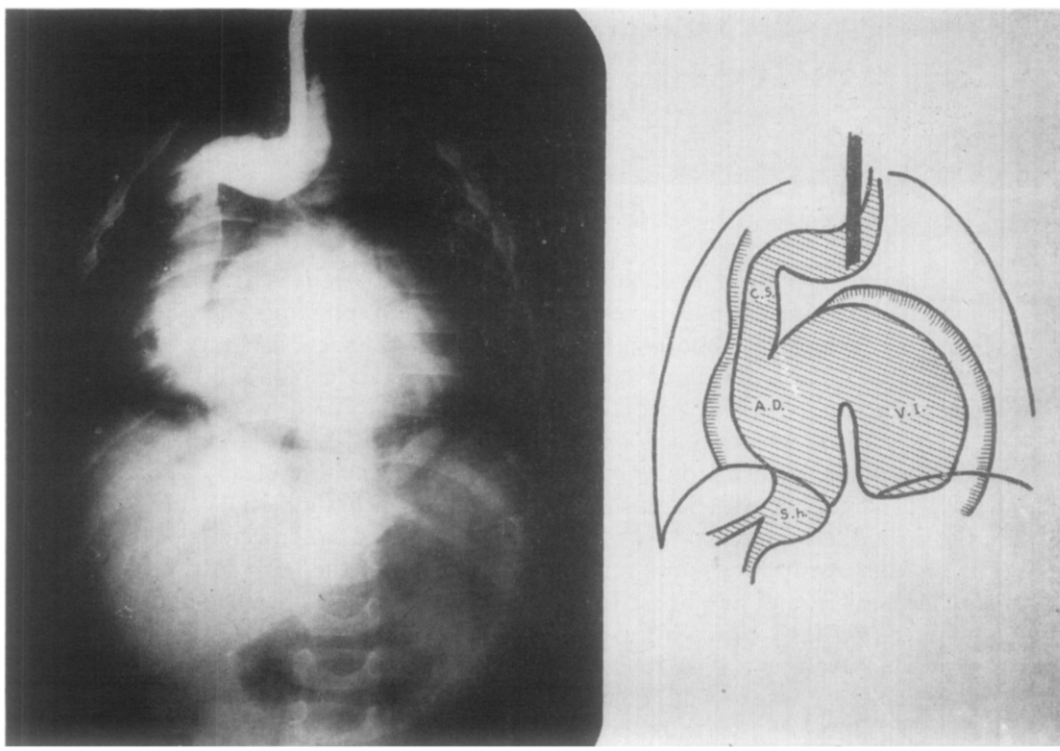

Fig. 32.—Angiocardiogram of same case shown in Figs. 30 and 31 (see text).

The films which we have described constitute, so far as we know, the first visualization of aortic coarctation that has been obtained in clinical medicine. This method gives valuable information concerning the site, degree, and extent of stenosis.

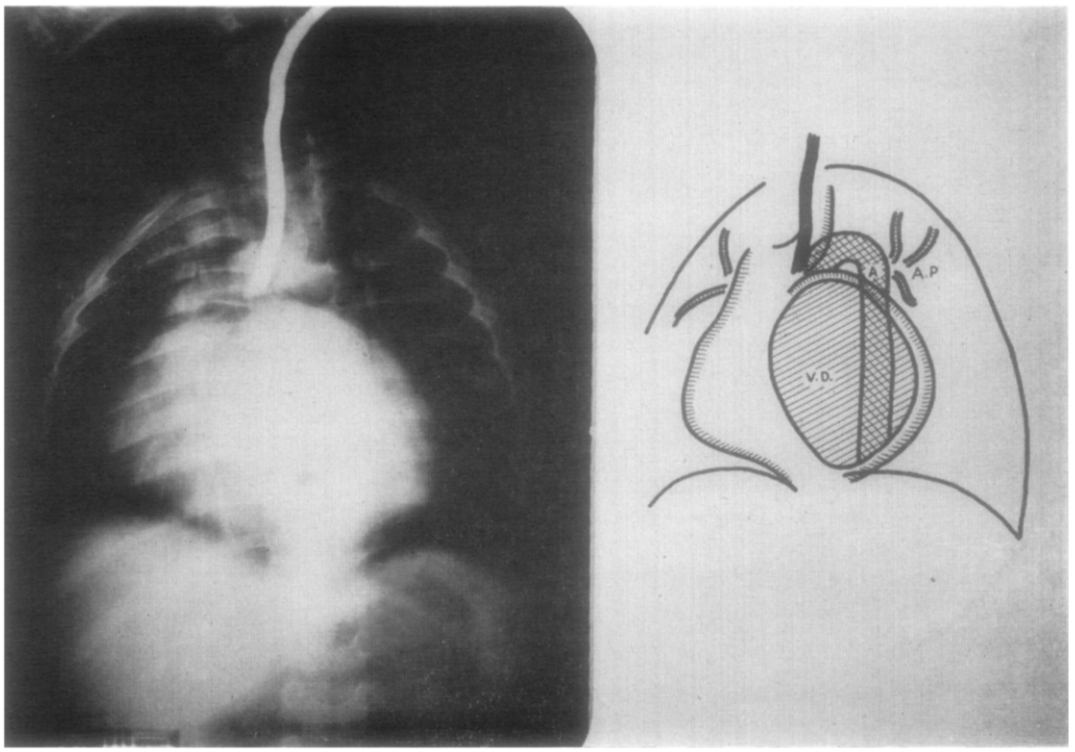

Fig. 33.—Angiocardiogram of same case shown in Figs. 30, 31, and 32 (see text).

Abnormal Images With Abnormal Routes of Flow.—It is in this field that the angiocardiographic method is of greatest value. It provides the only way of visualizing congenital abnormalities and atypical connections between the two circulations. The current of opaque substance may be followed through its abnormal route.

The patient whose film is shown in Fig. 30 is a 4-year-old child with congenital syphilis. He was intensely cyanotic and incapable of any effort. The heart was large. A systolic murmur, weak and somewhat musical, could be heard in the second left intercostal space and was transmitted to the vessels of the neck. The ordinary x-ray film shows marked enlargement of the left ventricle, a broad vascular pedicle, and an almost total lack of pulmonary trabeculae and vascular branches. Halfway through the injection (Fig. 31) the superior cava is visualized and appears large and displaced toward the right; its continuity with the right auricle is clear. One second later (Fig. 32), at the end of the injection, the right auricle is full as are the suprahepatic veins; but the left auricle and ventricle become filled at the same time. Still another second later (Fig. 33), the auricles

are already empty and only the enormous left ventricle, from which springs a narrow aorta, can be seen. At no instant was it possible to detect the right ventricle or the pulmonary artery. The few pulmonary vessels observed were seen to fill simultaneously with the aorta.

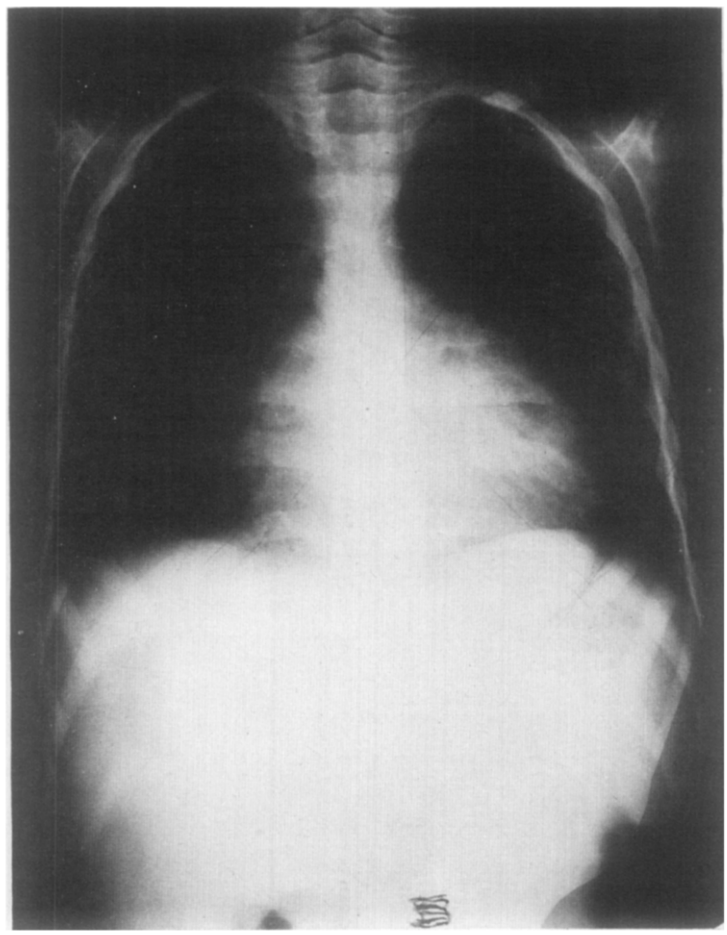

Fig. 34.—An ordinary x-ray film of a 4-year-old child with tricuspid atreasia and cor triloculare with persistence of the truncus arteriosus.

The angiocardiographic data are eloquent: there is no right ventricle and no pulmonary artery, and both auricles are amply connected. The left ventricle is isolated and enormous. Clearly there exists a *cor biloculare*, or at most a *cor triloculare biatriatum*, with persistence of a single arterial trunk.

A somewhat similar case (Fig. 34) is that of another 4-year-old boy, very cyanotic since birth and with a soft systolic thrill and a harsh and loud systolic murmur at the second left intercostal space. The picture suggested a complex malformation with stenosis of the pulmonary artery, perhaps a tetralogy of

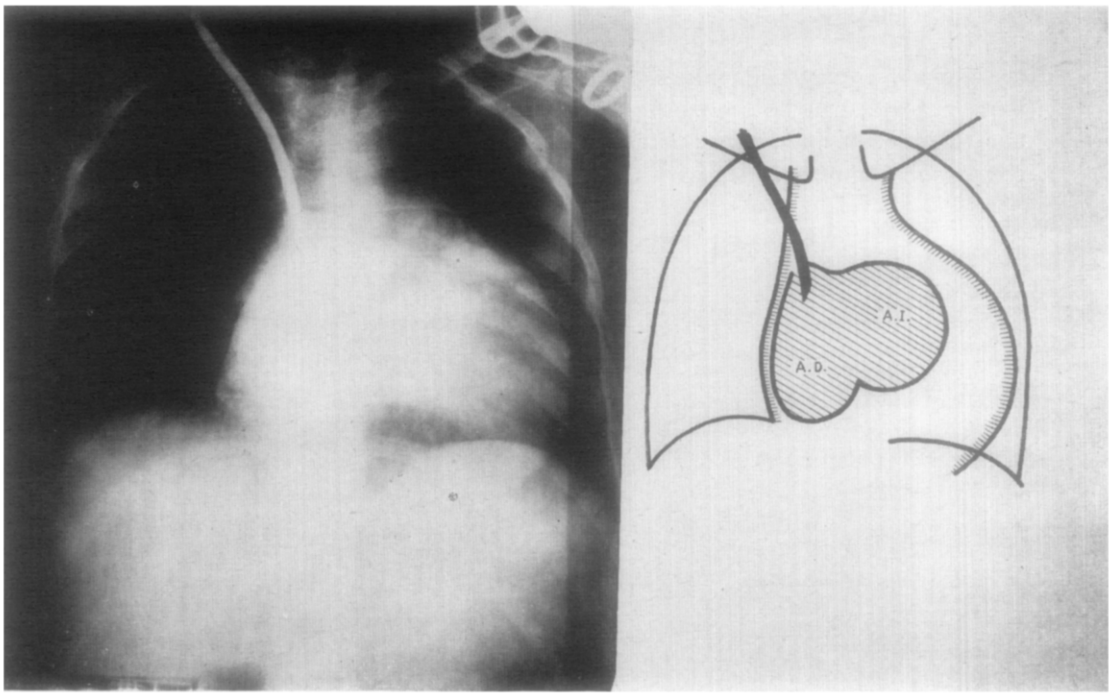

Fig. 35.—Angiocardiogram of same case shown in Fig. 34 (see text).

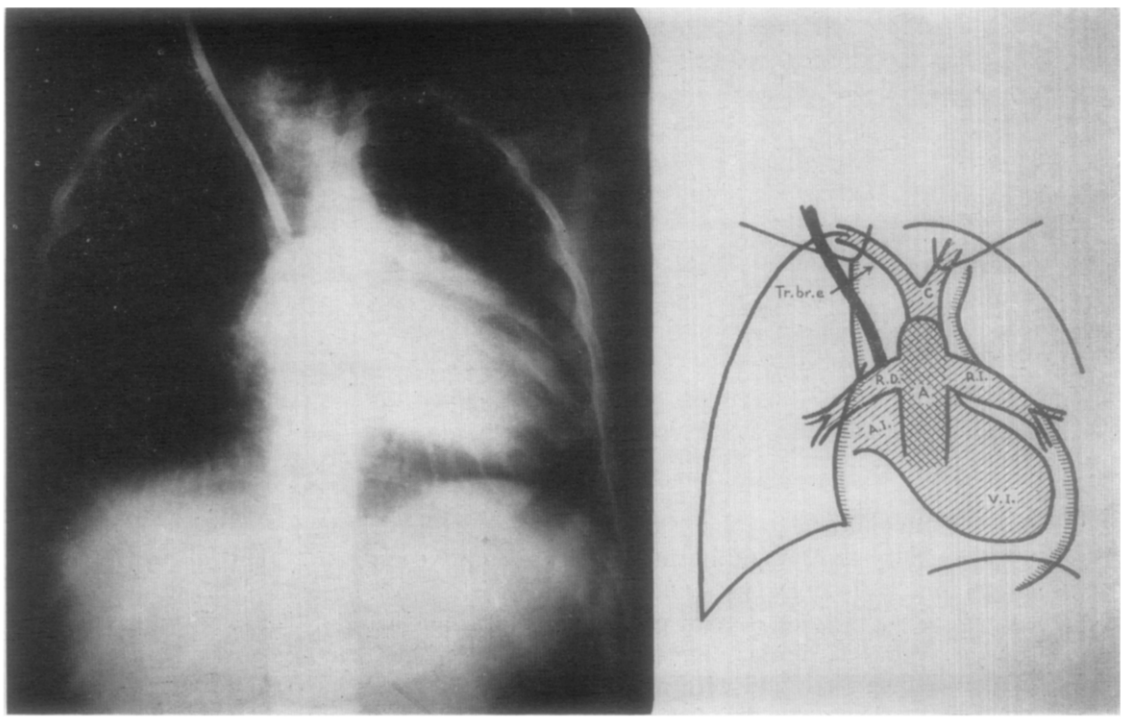

Fig. 36.—Angiocardiogram of same case shown in Figs. 34 and 35 (see text).

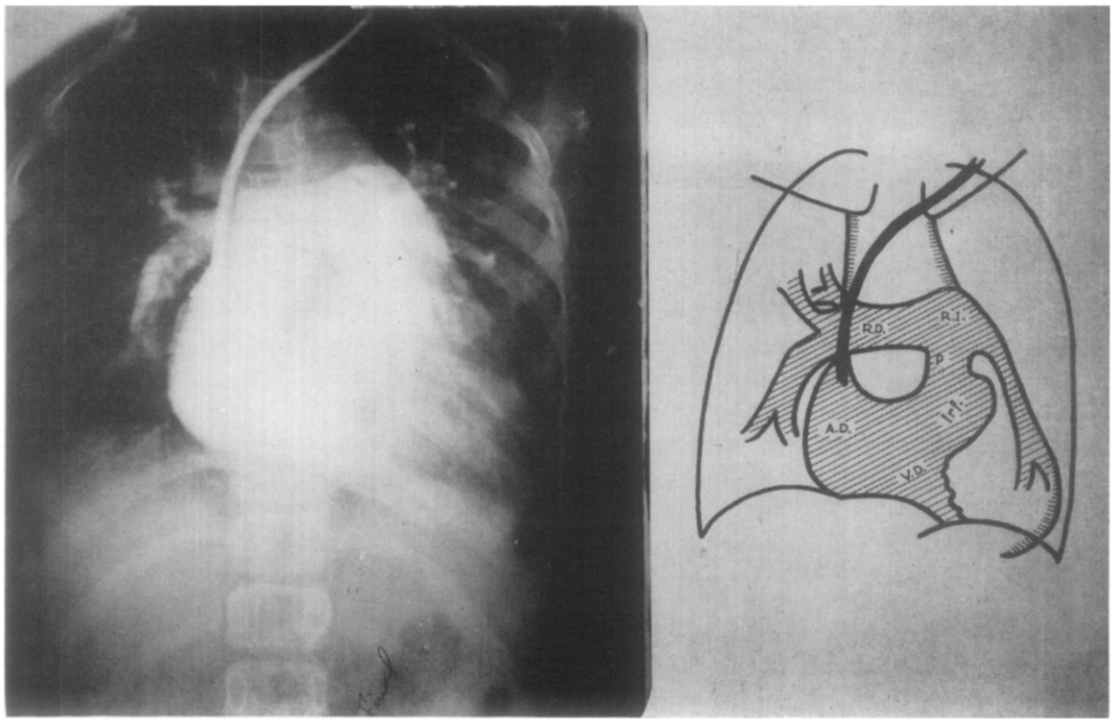

Fig. 37.—Angiocardiogram of patient with patent ductus arteriosus.

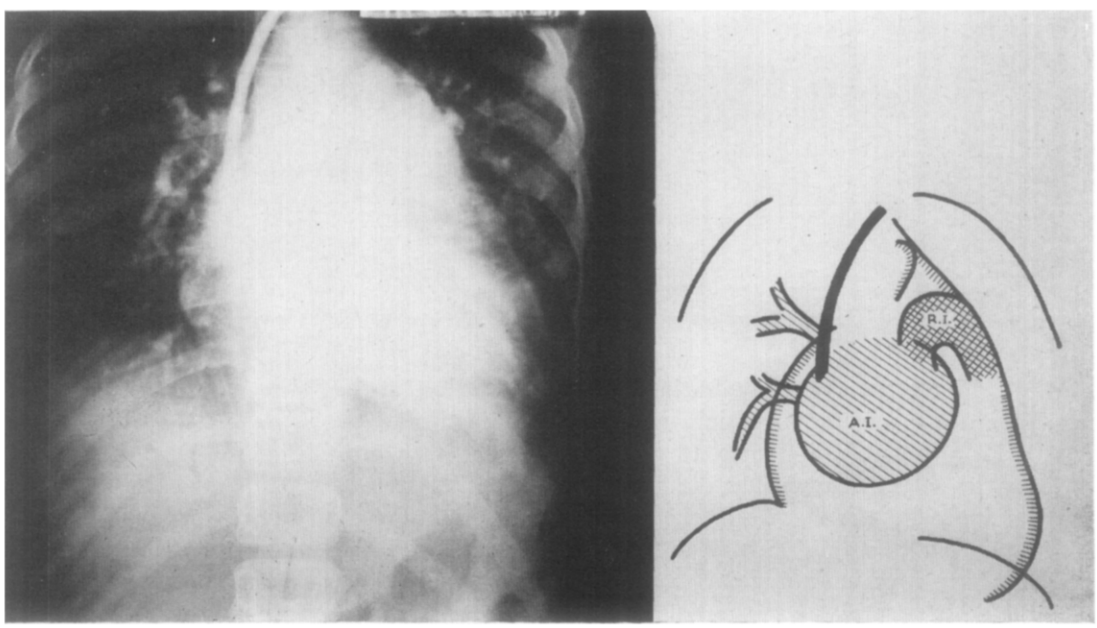

Fig. 38.—Angiocardiogram of same case shown in Fig. 37 (see text).

Fallot. Halfway through the injection (Fig. 35), both auricles are visualized and appear full and connected with each other, but separated by a clear notch. Subsequent plates, taken at one-second intervals, show a very hypertrophied left ventricle which fills first, and is then followed by filling of the aorta (Fig. 36). The left ventricle occupies a medial position and gives rise to two pulmonary branches. At no time was an image of the right ventricle obtained. These findings indicated a diagnosis of *tricuspid atresia* and *cor triloculare* with *persistence of the truncus arteriosus* instead of Fallot's tetralogy, which had appeared certain.

When Fallot's malformation or Roger's disease is actually present, the images are conclusive. Since we have studied mainly adults, we do not yet have any images of our own. The beautiful plates obtained by Castellanos[6-8] with his own methods may be consulted.

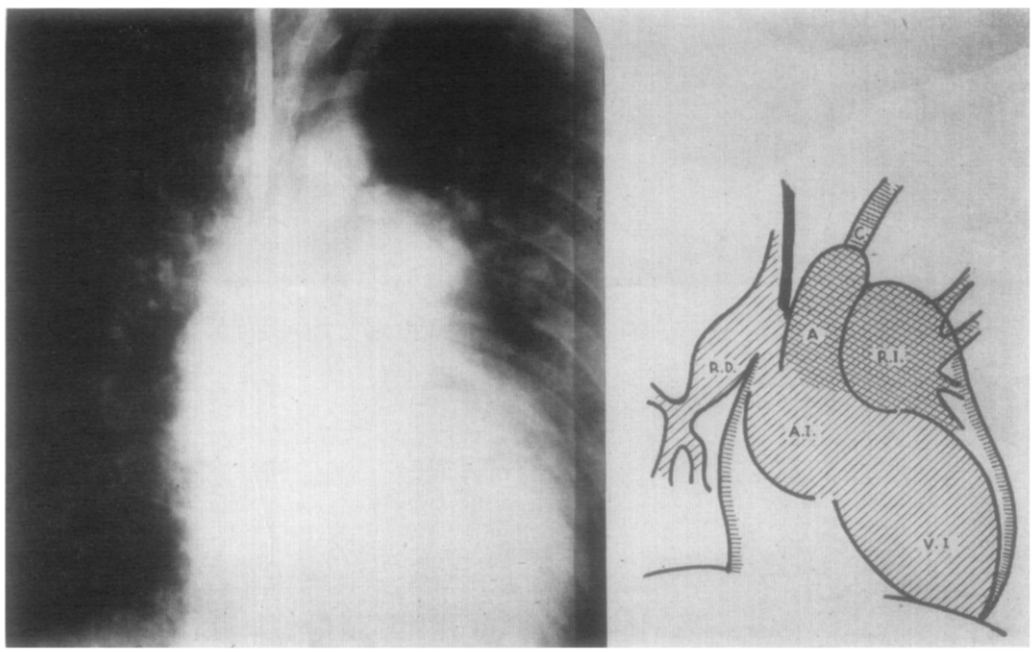

Fig. 39.—Angiocardiogram of same case shown in Figs. 37 and 38 (see text).

Finally, a new contribution of the method we are recommending and are presenting for the first time is its aid in diagnosing *patent ductus arteriosus.* It is not possible, of course, to visualize the duct itself, since it is usually so short that even the surgeon has difficulty in seeing it. The evidences of its existence are indirect. In Fig. 37, at the end of the injection, the right cavities are seen to be normal and full, with an accentuated prominence of the main trunk and the left branch of the pulmonary artery. Two seconds later, the pulmonary vessels are still full and the left auricle begins to appear. Two seconds later still (Fig. 38), the left auricle is clear and the left ventricle is beginning to fill. The opacity

of the pulmonary artery decreases from one plate to another. But in the next plate (Fig. 39), taken six seconds after the injection, in which the left ventricle as well as the aorta are totally opaque, the trunk and branches of the pulmonary artery, instead of completing the emptying initiated in the previous plates, again become opaque. This delayed back-flow filling of the pulmonary artery, at the time that the aorta fills, is a decisive radiologic sign: it is only possible if there is a fistulous connection between the two vessels. It is unnecessary to emphasize the importance of this sign in doubtful cases, especially now that this diagnosis carries with it the practical implication of surgical intervention.

REFERENCES

1. Forssmann, W.: Die Sondierung des rechten Herzens, Klin. Wchnschr. **8**:2085, 1929.
2. Forssmann, W.: Nachtrag zur der Arbeit, Klin. Wchnschr. **8**:2287, 1929.
3. Pérez Ara, A.: El Sondaje del Corazón Derecho, Rev de méd. y cir. de la Habana **36**:7, 1931.
4. Padilla, T., Cossio, P., and Berconsky, I.: Semana méd. **28**:5, 1932; **32**:11, 1932; **33**:29, 1932; **36**:41, 1932.
5. Egaz Moniz, Lopo de Carvalho, and Saldanha, A.: Angiopneumographie, J. de radiol. et d'électrol. **16**:469, 1932.
6. Castellanos, A., Pereiras, R., and García, A.: La Angiocardiografía, un método nuevo para diagnóstico de las cardiopatías congénitas, Archivos de la Sociedad de estudios clínicos de la Habana, 1937.
7. Castellanos, A., Pereiras, R., and García, A.: La Angiocardiografía en el niño, Séptimo Congreso de la Asociación Médica Pan Americana de la Habana, 1938.
8. Castellanos, A., Pereiras, R., and García, A.: L'Angiocardiographic Chez L'enfant, Presse méd. **80**:25, 1938.
9. Robb, G., and Steinberg, M. F.: Visualization of the Chambers of the Heart, the Pulmonary Circulation and Great Blood Vessels in Man; A Practical Method, Am. J. Roentgenol. **41**:1, 1939.
10. Thompson, S. A.: Differential Diagnosis by Means of Intravenous Contrast Medium of Two Cases Simulating Aneurysm of the Pulmonary Artery, Am. J. Roentgenol. **46**:646, 1941.
11. Steinberg, M. F., Grishmann, A., and Sussmann, M. L.: Angiocardiography in Congenital Heart Diseases, Am. J. Roentgenol. **48**:141, 1942.
12. Taylor, H. K., and Shulman, I.: Cardio-Angiography, Radiology **39**:323, 1942.
13. Steinberg, M. F., Grishmann, A., and Sussmann, M. L.: Angiocardiography in Congenital Heart Diseases. Patent Ductus Arteriosus, Am. J. Roentgenol. **50**:306, 1943.
14. Grishmann, A., Sussmann, M. L., and Steinberg, M. F.: Angiocardiographic Analysis of Cardiac Configuration in Rheumatic Mitral Disease, Am. J. Roentgenol. **51**:33, 1944.
15. Grishmann, A., Steinberg, M. F., and Sussmann, M. L.: A Typical Coarctation of the Aorta, With Absence of Left Radial Pulse, AM. HEART J. **27**:217, 1944.