fluorescent fungus. A series of individuals were studied in New York as controls on the case seen here, but all were negative.

The fungus apparently belongs to the *Aspergillus glaucus-repens* group. More intensive studies of its biologic properties are now being made in two separate institutions, with the idea of determining its identity. The fungus may prove to be a well known organism that becomes pathogenic only under certain limited conditions.

The fluid medium in which the fungus has been growing for from two to three weeks becomes light brown and is strongly acid in reaction. When the medium is made slightly alkaline, it becomes strongly fluorescent. Frequently, a red pigment is also produced. The fluorescent substance was soluble in nearly all of the lipoid solvents. It can be readily extracted from the medium by means of ether or ethyl acetate. The medium must be acid in reaction at the time of extraction with the solvent. From the solvent, it can be easily removed by means of weak alkalis. In these alkaline washings, which are, of course, now free from most of the other constituents of the medium in which it has been growing, the fluorescence is very marked.

Photodynamic experiments were conducted with the extracts obtained with ether or ethyl acetate. The ether extracts obtained by extracting the cultures were evaporated over a small amount of sodium chlorid solution at a low temperature. The photodynamic action of the extracts thus obtained was tested first on the potassium iodid-starch mixture, and was found to be active in the light and inactive in the dark. When a series of mice were inoculated, those exposed to the light soon developed edema and reddening of the ears, and swelling and edema of the eyelids. In a few experiments, death quickly followed exposure to sunlight. If the inoculations were continued daily, with repeated exposure to bright light, the ears became gangrenous and dropped off, the tail became rough and scaly and there was some loss of hair from the face and head. The greatest difficulty encountered in these experiments was in determining the strength of the solutions used, for we had no way of standardizing them. Dr. Johnson showed that paramecia also were susceptible to the photodynamic action of these extracts. Attempts were made to infect the animals by feeding, but without success.

CONCLUSIONS

Our observations will not permit us to agree that in all cases of pellagra there was an insufficient amount of animal protein in the diet previous to the onset of the disease; but we do believe that the individuals observed probably consumed an excess of carbohydrates, and, for this reason, we favor the idea advanced above. Those conversant with the diet of people living in the Southern states must have been impressed with the excessive amount of carbohydrates consumed, and this appears to hold true for the warmer countries throughout the world. This does not mean that these people do not obtain a sufficient amount of animal protein.

We have given some of the results obtained during the last three years in the attempted development of a hypothesis which we believe will reconcile some of the opposed views about pellagra. It is not our desire to claim, or even to suggest, that we have discovered the cause of pellagra. We realize that such a claim could be made only after it had been demonstrated that the organism could be isolated in the majority of a large number of pellagra cases, and that it does not occur in nonpellagrous individuals. The decrease in the disease renders this task impossible for us, so it was thought best to report the results we have obtained up to date, and let others, if they so desire, carry on the work.

ROENTGENOGRAPHY OF URINARY TRACT DURING EXCRETION OF SODIUM IODID *

EARL D. OSBORNE, M.D.
CHARLES G. SUTHERLAND, M.B. (TOR.)
ALBERT J. SCHOLL, JR., M.D.
AND
LEONARD G. ROWNTREE, M.D.
ROCHESTER, MINN.

There is need of a simple and painless method of depicting the urinary tract, bladder, kidneys and ureters. By the use of catheters and various opaque

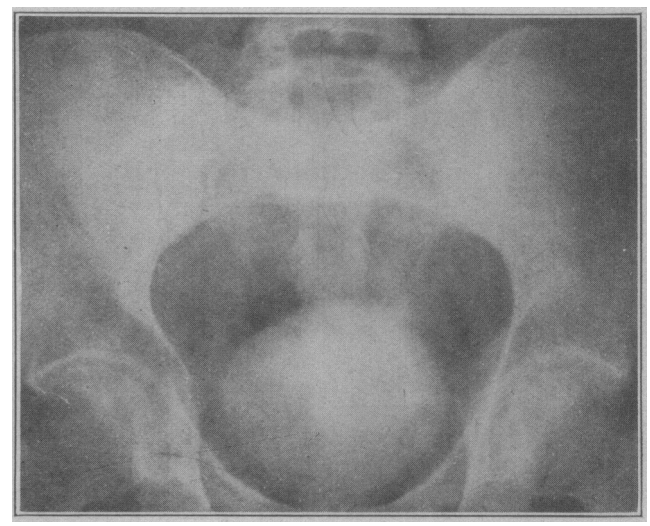

Fig. 1.—The patient received 200 c.c. of a 10 per cent. solution of sodium iodid intravenously. The roentgenogram made two hours later revealed a perfect outline of the full bladder.

mediums, success has been attained so far as the bladder, ureters and pelves of the kidney are concerned. Cystography and urography, while of great importance, are not without drawbacks and limitations. The use of the urethral or ureteral catheter is subject to obvious objections from both the physician's and the patient's standpoint. Technically, ureteral catheterization is at times very difficult, and it often subjects the patient to excruciating pain and occasionally to serious reactions. While pyelography may clearly delineate the renal pelves, it may fail to reveal the outline of the kidney itself. In surgical and medical diseases of the kidney, information concerning the size and location of these organs is of paramount interest. In nephritis, for example, it would be of decided value to be able to ascertain definitely during the patient's life whether his kidney is large, small or contracted, or of normal size. While the kidneys may be clearly outlined by inducing a pneumoperitoneum, and possibly by injecting air locally into the renal

* From the Division of Medicine, Mayo Clinic.

regions, these procedures, for obvious reasons, are not likely to be practiced generally.

It occurred to one of us (L. G. R.) that if, in roentgenography of the urinary tract, advantage could be taken of the fact that sodium iodid, after its introduction into the body, is normally excreted in the urine, roentgenograms of the kidneys, ureters and bladder might be secured without the need of catheterization. An ideal opportunity for the clinical testing of this idea presented itself in the section on dermatology and syphilology of the Mayo Clinic, where one of us (E. D. O.) was utilizing intravenously from 50 to 250 c.c. of a 10 per cent. solution of sodium iodid in the study of the pharmacology and therapeutics of iodids. This circumstance made possible an immediate and direct clinical study, eliminating the necessity of carrying out time-consuming preliminary investigations on animals. The patients were informed of our interest in this problem, and many of them volunteered to undergo the roentgen-ray studies.

THE INTRODUCTION OF VARIOUS MEDIUMS IN THE URINARY TRACT

Voelcker and Lichtenberg,[1] in 1906, were the first to report the use of an opaque roentgenographic medium, injected into the pelvis of the kidney for the purpose of determining the pelvic outline. Colloidal silver, the medium suggested by them, was dirty and expensive, and it often caused severe reactions. In 1915, Burns [2] reported very satisfactory results with thorium nitrate. Various other chemical compounds were suggested, but none were satisfactory. The proprietary preparations were expensive and often caused marked reactions. The work of Braasch and Mann [3] has demonstrated that practically all the silver compounds, when retained in the pelvis of the kidney or injected under pressure, produce areas of cortical necrosis. In some instances, it has been possible to find definite deposits of the metal in the renal cortex. Praetorius,[4] who suggested the use, as a medium, of a preparation claimed to contain colloidal silver iodid, cites twelve deaths, previous to 1917, from the use of colloidal silver. Later, Schüssler [5] and Barreau [6] reported severe reactions from the use of the preparation claimed to contain colloidal silver iodid.

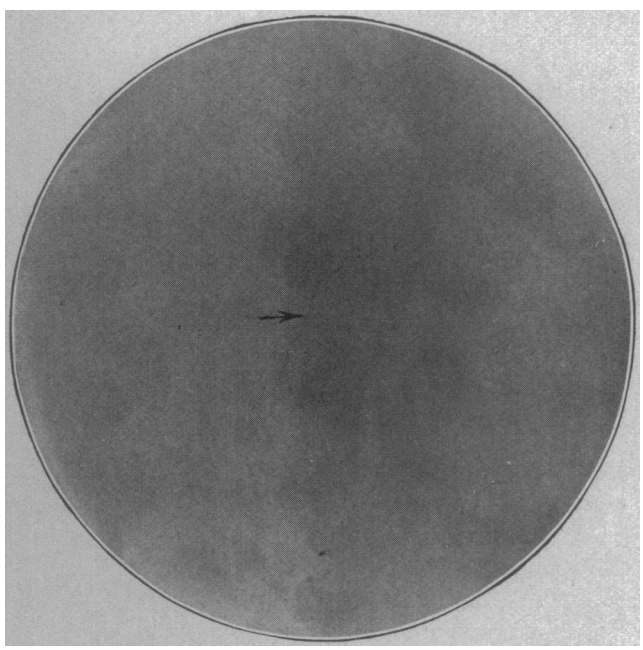

Fig. 2.—The patient received 135 c.c. of a 10 per cent. solution of sodium iodid intravenously. The roentgenogram made one and one-half hours later contained shadows of the pelvis, the major calices and a portion of the ureter on both sides.

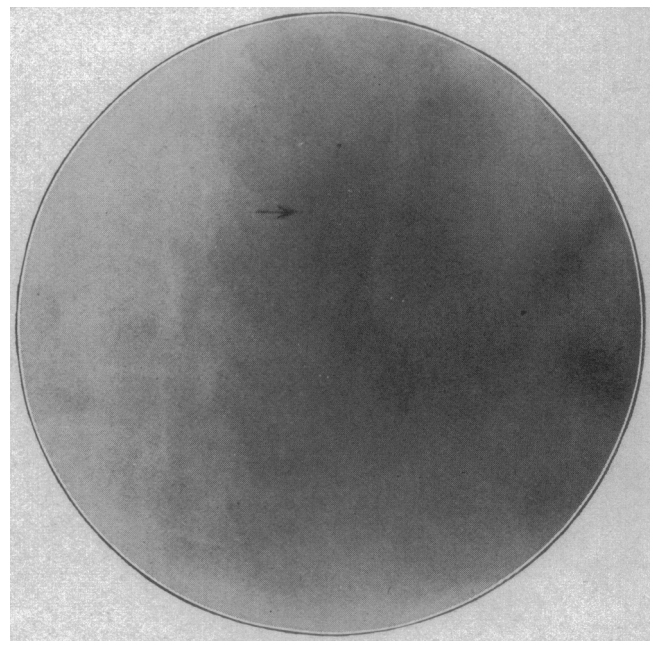

Fig. 3.—The patient received 100 c.c. of a 10 per cent. solution of sodium iodid intravenously. The roentgenogram made one hour later contained a definite outline of the pelvis of the left kidney, with the ureter from 4 to 6 cm. distant from the kidney hilus.

Kelly and Lewis,[7] in 1913, were the first to suggest the use of an iodid as a medium. They recommended silver iodid emulsion. Sodium iodid as a medium in roentgenography was introduced by Cameron [8] in 1918. The striking lack of toxicity of sodium iodid has long been known, but not fully appreciated. Enormous doses have been used clinically by syphilologists in the treatment of syphilis. Experimentally, the lack of toxicity of the iodids was illustrated recently by Weld,[9] who found that toxic effects did not follow the administration intravenously of 50 c.c. of a 25 per cent. solution to dogs weighing 6 kg. Weld suggested the use of sodium bromid, which is now generally used for depicting the renal pelves and ureters in urologic examinations at the Mayo Clinic. Sodium bromid causes fewer reactions than sodium iodid, but does not give such clear roentgenographic outlines. Sodium

1. Voelcker, F., and Lichtenberg, A.: Pyelographie (Roentgenographie des Nierenbeckens nach Kollargolfüllung), München. med. Wchnschr. **53**: 105-107, 1906.
2. Burns, J. E.: Thorium, a New Agent for Pyelography, Preliminary Report, J. A. M. A. **64**: 2126-2127 (June 26) 1915.
3. Braasch, W. F., and Mann, F. C.: Effects of Retention in the Kidney of Media Employed in Pyelography, Am. J. M. Sc. **152**: 336-347 (Sept.) 1916.
4. Praetorius, G.: Pyelographie mit kolloidalem Jodsilber ("Pyelon"), Ztschr. f. Urol. **13**: 159-168 (April) 1919.
5. Schüssler, H.: Zur Pyelographie mit "Pyelon," München. med. Wchnschr. **67**: 750-751 (June 28) 1920.
6. Barreau, E.: Zur Frage der Pyelographie, Ztschr. f. Urol. **15**: 134-144, 1921; Ueber Pyelon, ibid. **15**: 507, 1921.
7. Kelly, H. A., and Lewis, R. M.: Silver Iodide Emulsion—a New Medium for Skiagraphy of the Urinary Tract, Surg., Gynec. & Obst. **16**: 707-708, 1913.
8. Cameron, D. F.: Aqueous Solutions of Potassium and Sodium Iodids as Opaque Mediums in Roentgenography, Preliminary Report, J. A. M. A. **70**: 754-755 (March 16) 1918; A Comparative Study of Sodium Iodid as an Opaque Medium in Pyelography, Arch. Surg. **1**: 184-214 (July) 1920.
9. Weld, E. H.: The Use of Sodium Bromid in Roentgenography, J. A. M. A. **71**: 1111-1112 (Oct. 5) 1918; Toxicity of Pyelographic Mediums, Report of a Death Following the Use of Thorium Nitrate, J. Urol. **3**: 415-426 (Oct.) 1919. Renal Absorption with Particular Reference to Pyelographic Mediums, Med. Clin. N. America **3**: 713-731 (Nov.) 1919.

bromid, like sodium iodid, is of such low viscosity that it often runs from the pelvis and ureter before the roentgenogram is completed.

METHOD OF ADMINISTRATION OF SODIUM IODID

Intravenous Administration.—The method of intravenous administration of sodium iodid has been employed in the section on dermatology and syphilology since 1918. The patient is first given 15 grains (about 1 gm.) of potassium iodid by mouth, three times a day for two days, in order to determine whether there is an idiosyncrasy to the drug. If no symptoms of acute iodism occur, the intravenous injection of a 10 per cent. solution is begun, the third day.

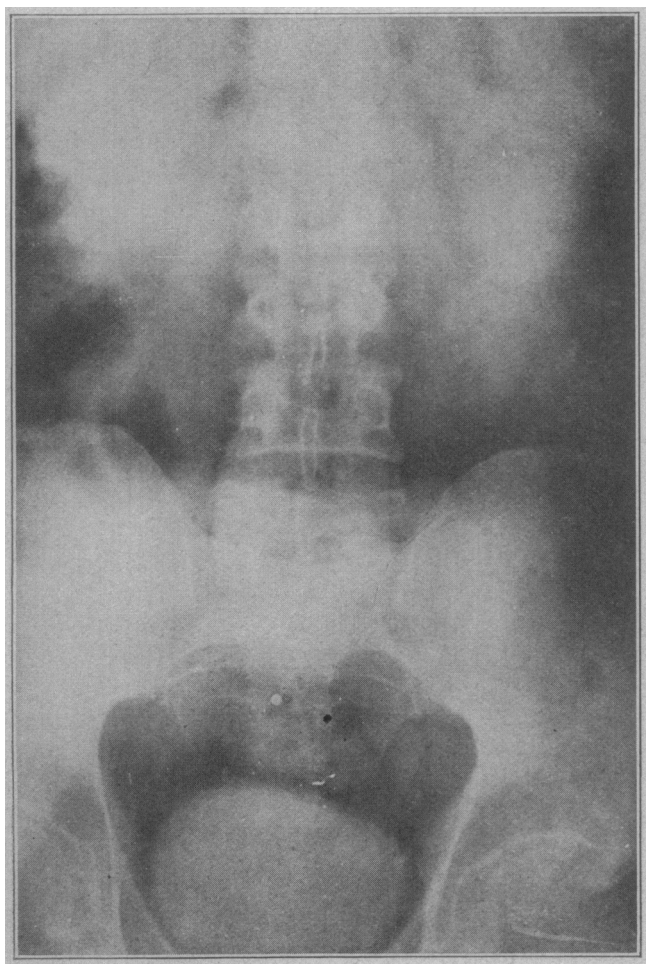

Fig. 4.—The patient received 100 c.c. of a 10 per cent. solution of sodium iodid intravenously. The roentgenogram made one and one-half hours later revealed a perfect outline of a full bladder, and an outline of the pelvis of the left kidney with a suggestion of the calices and the ureter for a distance of from 3 to 4 cm. below the hilum of the kidney. The right kidney area was obscured by gas in the colon.

Various dosages have been employed, ranging from 5 to 20 gm. of a 10 per cent. solution of chemically pure sodium iodid. As Osborne has pointed out, 10 gm. may be given to practically every patient without untoward symptoms, provided the injection is not too rapid, that is, not completed in less than four or five minutes. With a dose of more than 10 gm., symptoms appear, probably due to osmotic changes resulting from large amounts of the hypertonic salt solution. It would seem that 10 gm. is a fair dose for the average routine case. Naturally, the usual contraindications to iodids apply here; that is, patients with tuberculosis, adenomatous thyroids, exophthalmic goiter and marked debility are not good subjects for this form of treatment. Generally speaking, our results following the intravenous administration of sodium iodids may be summarized thus:

1. Satisfactory roentgenograms of the bladder were secured in practically every case with doses of from 5 to 20 gm. intravenously.

TABLE 1.—IODIN IN THE URINE AFTER SODIUM IODID INTRAVENOUSLY

	Sodium Iodid, 5 Gm.			Sodium Iodid, 10 Gm.			Sodium Iodid, 20 Gm.		
		Iodin Excreted			Iodin Excreted			Iodin Excreted	
Time After	Urine, C.c.	Per Cent.	Mg. per 100 C.c.	Urine, C.c.	Per Cent.	Mg. per 100 C.c.	Urine, C.c.	Per Cent.	Mg. per 100 C.c.
15 min.	9.5	1.2	5.6	43.0	1.2	2.5	55.0	0.5	1.6
30 min.	17.5	3.5	**8.5**	21.5	1.9	7.8	40.0	0.6	2.8
45 min.	16.5	2.9	**7.4**	21.5	2.5	**10.0**	26.0	0.5	3.8
1 hr.	14.0	2.0	6.3	22.5	2.7	**10.2**	25.5	1.0	7.0
2 hrs.	77.5	8.8	4.9	95.0	8.7	7.7	146.0	8.4	**9.8**
3 hrs.	54.0	5.4	4.4	106.0	5.2	4.2	104.0	7.7	**12.7**
4 hrs.	43.0	6.4	6.2	93.0	2.5	2.2	133.0	10.4	**13.3**
6 hrs.	....	...	...	25.0*	1.9	5.9			
7 hrs.	218.0	16.5	3.2	....	...	...	225.0	15.6	11.8
8 hrs.	....	...	...	102.0	8.7	7.2			
18 hrs.	490.0	19.5	1.6	473.0	17.6	3.2	375.0	23.4	10.5
24 hrs.	245.0	10.0	1.7	590.0	6.6	0.9	151.0	8.1	7.5
48 hrs.	1055.0	14.7	0.59	965.0	15.5	1.4	1080.0	13.9	1.2
72 hrs.	960.0	2.8	0.12	1005.0	4.6	0.3	1030.0	3.7	0.6
96 hrs.	995.0	0.5	0.02	1120.0	0.3	0.02	975.0	0.1	0.01
120 hrs.	1010.0	Trace	....	945.0	Trace	....	950.0	Trace	
In 24 hrs.....		76.2	....	.....	59.5	....	.....	76.2	
In 48 hrs.....		90.9	....	.....	75.0	....	.....	90.1	
In 72 hrs.....		93.7	....	.....	79.6	....	.....	93.8	
In 96 hrs.....		94.2	....	.....	79.9	....	.....	93.9	

* Approximately four fifths of this specimen was lost.

2. Ten gram doses of sodium iodid intravenously gave fair roentgenograms of the kidneys and ureters in approximately 50 per cent. of the cases, and occasionally of the liver and spleen.

3. The best roentgenograms of the upper urinary tract and of the spleen and liver were secured with the use of large doses, that is, from 15 to 20 gm.

The time elapsing between the administration of the sodium iodid and the taking of the roentgenogram is of vital importance. Table 1 shows the amount and

TABLE 2.—URINARY EXCRETION OF IODIN AFTER SODIUM IODID BY MOUTH

	Sodium Iodid, 1 Gm.			Sodium Iodid, 5 Gm.			Sodium Iodid, 20 Gm.		
		Iodin Excreted			Iodin Excreted			Iodin Excreted	
Time After	Urine, C.c.	Per Cent.	Mg. per 100 C.c.	Urine, C.c.	Per Cent.	Mg. per 100 C.c.	Urine, C.c.	Per Cent.	Mg. per 100 C.c.
Before	Sample	Trace	....	Sample	Trace	....	Sample	Trace	
1 hr.	59.0	5.3	0.76	77	7.3	**4.03**	296	10.9	**6.34**
2 hrs.	46.0	8.6	**1.58**	52	7.1	**5.60**	122	6.2	**8.42**
3 hrs.	52.0	7.1	**1.29**	119	9.9	**3.51**	63.5	1.6	**4.24**
4 hrs.	45.5	6.3	**1.32**	212	6.8	1.35			
6 hrs.				365	18.5	2.14	252	4.4	2.97
10 hrs.	300	24.0	0.75	226	11.0	2.06	886	30.9	5.9
24 hrs.	470	26.7	0.53	433	23.7	2.32	734	23.6	5.4
48 hrs.	910	12.6	0.13	843	12.1	0.61	1120	14.2	2.1
72 hrs.	...	....	....	895	2.4	0.10	955	5.7	0.8
96 hrs.	...	....	....	990	0.4	0.01	885	0.2	0.04
120 hrs.	...	....	....	1120	Trace	Trace	1060	Trace	Trace

concentration of iodin in the urine at varying intervals following the intravenous administration of 5, 10, and 20 gm. doses of a 10 per cent. solution of sodium iodid. The highest point of concentration following a dose of 5 gm. is in the second fifteen minute interval, when 8.5 mg. of iodin was excreted in each cubic centimeter of urine. With a dose of 10 gm., this amount rose to 10.2 mg. of iodin for each cubic centimeter of urine during the third fifteen minute interval, and following the 20 gm. dose, to 12.7 mg. during the second hour and 13.3 mg. during the third hour. From

these data, it is seen that the roentgenograms should be taken one-half hour, one hour and two or three hours after doses of 5, 10, and 20 gm., respectively. Our best results have been obtained by following this procedure, based on an actual determination of the rate of excretion of sodium iodid.[10]

Administration by Mouth.—It was at first thought that roentgenograms of the urinary tract, following administration of sodium iodid by mouth, would be of no value because of the shadows cast by the drug in the stomach and in the small intestine. The contrary has been shown, however, when the proper technic is employed and attention is paid to the time interval between the administration of the iodid and the making of the roentgenogram. Satisfactory roentgenograms have been obtained at one and two hour intervals following a single large dose of 10 gm. of sodium iodid. This method, however, is not applicable to routine cases because of the local gastric upset following the ingestion of such large amounts of the salt. Our best results have been obtained by administering 3 gm. of sodium iodid hourly for three hours and taking the roentgenograms from one hour to two hours after the last dose. The rationale of this procedure is shown in Table 2. The urinary concentration of iodin following the oral administration of sodium iodid becomes highest during the one hour to three hours after the ingestion of from 1 to 5 gm. of the salt.

The patient is prepared in the routine manner for roentgen-ray examination of the urinary tract. At 8 a. m. he is instructed to take the first powder, consisting of 3 gm. of the sodium iodid, well diluted in from one to two glasses of water. He is instructed to empty the bladder at this time and not to pass more urine until the examination is completed. At 9 a. m. and at 10 he repeats the procedure, and at 11 the first roentgenogram is made, after which he is instructed to void as much urine as possible. This is measured and a second roentgenogram is made. It may be that the administration of large doses of sodium iodid will yield uniformly better results, but such has not been our experience. The employment of less than 3 gm. for each dose has not yielded satisfactory results except in a few instances.

In case the bladder alone is to be studied, the administration of a single dose of from 3 to 5 gm. of sodium iodid, without previous preparation, is all that is necessary. In this case the patient should be instructed not to void and the roentgenogram should be taken three hours after the ingestion of the drug. Results following the oral administration of sodium iodid may be summarized thus:

1. Very satisfactory roentgenograms were secured of the kidneys, pelves of the kidney, ureters and bladder in approximately 50 per cent. of cases, with repeated doses.
2. In a few cases the liver and spleen were also strikingly outlined.
3. Uniformly excellent results were obtained in the roentgenography of the bladder, following the repeated doses and after a single dose.

ROENTGENOLOGIC TECHNIC

In the first studies the technic routinely employed in the examination of the kidneys, ureters and bladder was used. Preliminary control roentgenograms were made before the administration of the sodium iodid. Plates 5 by 7 inches were used, without intensifying screens, one roentgenogram being made of each kidney area and one of the bladder area. A medium focus, standard Coolidge tube was used, with 60 kilovolts, 50 milliamperes, an average distance of 67.5 cm. from the target to the plate, and the time was varied from two to eight seconds according to the thickness of the patient. An aluminum compression cap, 12.5 cm. in diameter, fitted over the bottom of the cone, was clamped down as far as could be comfortably borne by the patient. Fairly satisfactory roentgenograms of thin, normal and even moderately stout subjects were obtained by this technic. The plates were marked with the patient's registration number and with the number of hours intervening since the administration of the sodium iodid. In some cases a series of roentgenograms was made at varying intervals after the administration. Another series of studies was made using duplitized films in intensifying screens, varying the kilovoltage and milliamperage according to the thickness of the subject, with uniformly better results, particularly in stout subjects. Control films were also made. Still another series was made using 14 by 17 inch duplitized films in intensifying screens with the Potter-Bucky diaphragm. A single film was made in a few cases; in the majority, two films were made, one high, to include the complete kidney area, and the other to include the bladder area. In this series, many films were made after the subjects had held the urine the allotted time; after they had emptied the bladder and the amount voided had been measured, a second film was made and marked with the amount voided. When actual retention occurred, it was depicted in the roentgenogram. The best uniform results were obtained with the Potter-Bucky diaphragm technic.

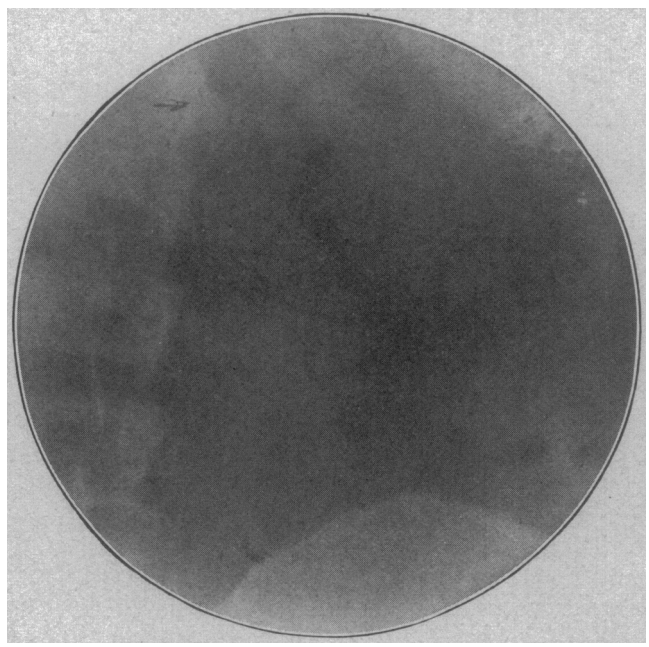

Fig. 5.—The patient received 100 c.c. of a 10 per cent. solution of sodium iodid intravenously. The roentgenogram made one hour later contained a definite shadow of the pelvis of the left kidney and the ureter for a distance of from 4 to 6 cm. below the hilum of the kidney. There was also a definite suggestion of the major calices.

10. These data and those dealing with the oral administration have been taken from work already published and work now in the process of publication by Osborne on the general subject of the pharmacology and therapeutics of iodids (Osborne, E. D.: Iodin in the Cerebrospinal Fluid, with Reference to Iodid Therapy, J. A. M. A. **76**: 1384-1386 (May 21) 1921; Contributions to the Pharmacology and Therapeutics of Iodids, ibid. **79**: 615-617 (Aug. 19) 1922; Contributions to the Pharmacology and Therapeutics of Iodids, II, to be published).

INTERPRETATION OF THE RESULTS

In some of the films and plates, because of gas in the colon or because of the thickness of the patient, it was not possible positively to identify the kidney and other solid organs. On the majority of the films

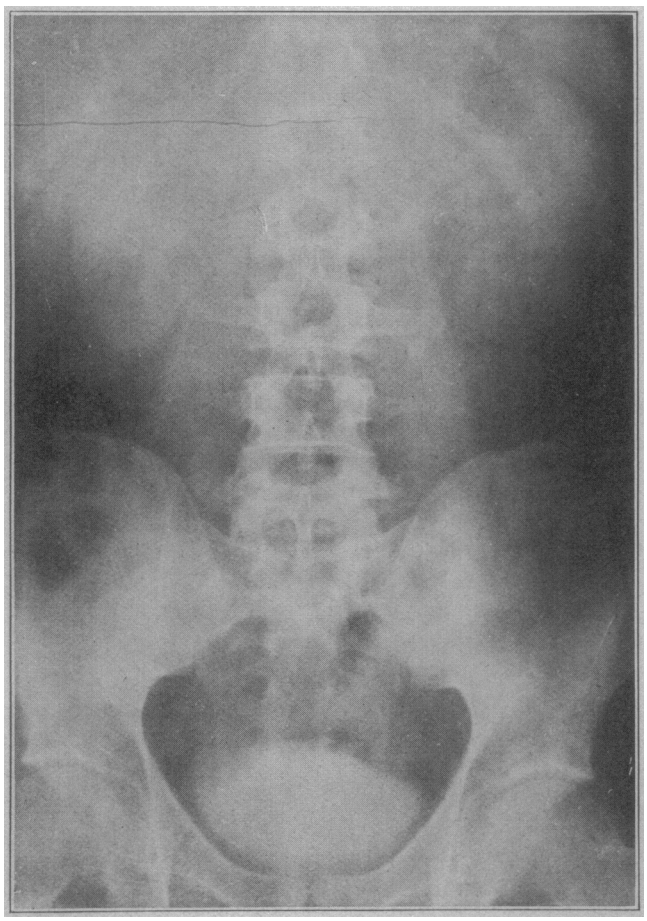

Fig. 6.—The patient received 100 c.c. of a 10 per cent. solution of sodium iodid intravenously. The roentgenogram made one hour later revealed a definite shadow of the partially filled bladder. The density of the kidneys, the spleen and the lower margin of the liver appeared to be increased over the normal. The pelves of both kidneys and the ureters for a distance of from 4 to 6 cm. from the hilum of the kidney were definitely outlined. On the right, there was a suggestion of the lower major calices.

and plates, the shadows of the kidneys, the lower margin of the liver and the spleen were sharply outlined, and it was our impression that, comparing the control plates and films with those made after the administration of the sodium iodid, there was a slight increase in the density of the shadow cast by these organs in the second plates and films of the series.

The pelvis of the kidney filled with iodid solution to varying degrees and the ureters could be traced in a number of instances, while in a few there was even a suggestion of the calices. In all of the plates and films the bladder was distinctly outlined and, as we have mentioned, retained iodid solution could be seen in patients with urinary retention. Obviously, only some of the better plates are shown in the accompanying illustrations.

COMMENT

The method described offers numerous possibilities in the field of research, not only with regard to the urinary tract, but also with regard to other systems, organs and tissues. We are firmly convinced that this investigation will serve as a stepping stone in other fields of study. The method affords an approach to the study of the physiology of the bladder, its form and position under varying degrees of distention, and the phenomena associated with distention and with emptying. It should also prove of decided value in the study of pathologic conditions of the bladder, such as diverticula, tumor and diseases secondary to disturbances in its innervation, or to obstruction in the lower urinary tract, such as stricture and enlarged prostate. In the study of the kidneys, the success of the method is only partial. It will be of assistance in a limited way, especially in determining the size, shape and position of these organs. It is too early and our results are too uncertain to determine whether the method has any value in the study of the liver and spleen.

Much is offered by this method in the study of the vascular system. Under the fluoroscope, the cephalic vein has the appearance of a steel wire, from the point of injection of the iodid at the elbow to the juncture of the cephalic vein with the subclavian. This has been noted following the use of 10 and 20 per cent. solutions of sodium iodid. In all probability, with variations in the technic, important results will be obtained with regard to the venous returns and the peripheral arterial circulation. In the study of aneurysm and of arteriovenous anastomosis, it should also be of value.

CONCLUSIONS

1. By the method described, it is possible to obtain roentgenograms of the urinary tract during the excretion of sodium iodid following its intravenous or oral administration.

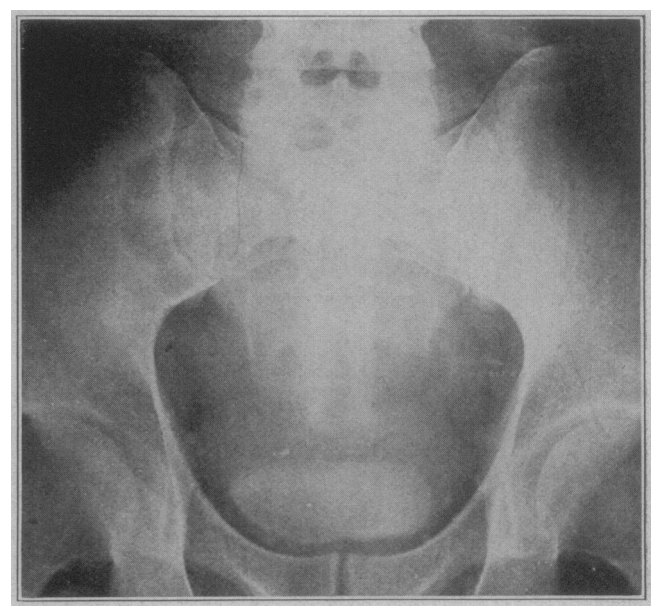

Fig. 7.—The patient received three 3 gm. doses of sodium iodid by mouth. Roentgenograms were made two hours after the last dose, and a shadow of the full bladder was obtained. The patient voided 125 c.c. of urine, and a roentgenogram was made which revealed retention that had not been suspected clinically. Further clinical study revealed the existence of a cord bladder.

2. The method uniformly gives excellent and accurate shadows of the urinary bladder and renders reliable information relative to its size, shape and location.

3. It has been partially successful in depicting the renal pelves and the ureters in a limited number of cases.

4. In a number of cases it assists in revealing the kidney itself through intensifying the renal shadow.

5. It has been proved a success in revealing the existence of residual urine in the bladder and in furnishing approximate information of the amount, thus eliminating the necessity of catheterization and its attendant dangers of infection.

6. Oral administration of the drug will prove satisfactory for routine use in making roentgenograms of the bladder, while for shadows of the ureters and kidneys intravenous injection of large doses of sodium iodid is desirable.

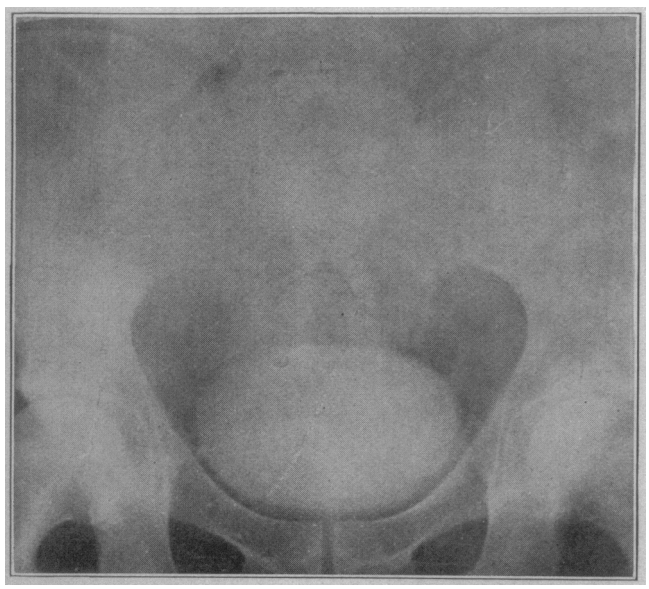

Fig. 8.—The patient received one dose of 5 gm. of sodium diodid by mouth, and a roentgenogram was made three hours after the ingestion of the drug. A perfect outline of the full bladder was revealed.

ACUTE BARBITAL (VERONAL) POISONING

REPORT OF CASE WITH FATAL OUTCOME

WILLIAM COLE, M.D.
ANAHEIM, CALIF.

Acute poisoning from barbital is apparently becoming more common in this country. This is probably due to the fact that the drug is so easily obtained without a physician's prescription. It is also due to the increase in the number of persons who seek hypnotic drugs in order to procure sleep; for it seems that the symptom of insomnia is becoming more common among all classes of our population.

That serious symptoms may arise from overdosage or prolonged use of barbital does not seem to be generally recognized even by the profession, but that this is so is attested by the cases reported in recent medical literature by Littell,[1] Hassin and Wein,[2] Taub[3] and Macleod.[4] Boenheim[5] states that, in a series of 286 cases of acute poisoning observed in Sick's service at Stuttgart in thirteen years, barbital was the drug taken in 5.7 per cent. of the cases, and five of the patients died. All of these had taken barbital in excess of 10 gm.

Acute barbital poisoning, in the absence of a history, may be easily mistaken for a number of other diseases giving rise to comatose states. This is especially true of epidemic (lethargic) encephalitis and certain cases of meningovascular syphilis. The case here reported illustrates most of the salient features in the symptomatology.

REPORT OF CASE

History.—R. H. M., a man, aged 39, married, white, an American, was admitted to the Anaheim Hospital, Oct. 16, 1921, in a state of profound coma. Friends who accompanied the patient stated that he had been found in a shack in the oil fields in this condition, and it was thought that possibly he had been overcome by carbon monoxid gas from a leaky gas stove used to heat the shack. Search of the patient's effects revealed a box containing twenty 5-grain (0.3 gm.) tablets of barbital, and a note to his wife expressing his intention of committing suicide. The patient's wife said he had always been in good health except for an attack of influenza in February, 1921, following which he had been subject to many "colds" and occasional attacks of mental depression. During the summer of 1921, his work had been very arduous, and he had undergone a good deal of mental strain.

Four weeks prior to admission, he consulted a physician on account of insomnia, and the latter prescribed barbital, 5 grains, to be taken at bedtime. He took one tablet each night for a week. At the end of the week, he had the prescription refilled, and he took two tablets each night for another week. Two weeks before admission, he went on a vacation, but he could not enjoy it because of insomnia, so he returned home after three days. October 11, he consulted another physician, who prescribed barbital. He also bought a box of barbital himself in Pasadena. His wife stated that he was at home every day for the six days preceding admission, and he appeared to be in normal health except that he looked worn out and was quite depressed because of insomnia. She said that he had taken six or seven of the tablets each day for the five days preceding his admission to the hospital. October 16, he resumed his work. That afternoon he was found unconscious and was brought to the hospital.

Physical Examination.—The patient was well developed. He was in profound coma. The temperature was 101 F. The face was cyanosed and the breathing stertorous, with the mouth open and the maxilla drawn down almost on the chest. The tendon reflexes were very lively. Muscular rigidity was marked. The pupils were round and equal, and reacted to light and to painful stimuli, such as pinching the neck. Hippus was present. No nystagmus was noted. The fundus oculi was normal. The Babinski sign and variants were negative on both sides, as was knee and ankle clonus. The cremasteric reflexes were present. The epigastric and abdominal reflexes were not obtained. At intervals, the patient moaned and moved the limbs. Shouting in his ears elicited no response. Painful stimuli of any degree failed to rouse him. Strong ammonia applied to the nostrils produced no defense movements or wrinkling of the face.

The radial pulse rate was 100. Both radial pulses were full, equal and regular. The blood pressure was: systolic, 145; diastolic, 95. The heart showed no abnormalities. At intervals, there was profuse perspiration. Respirations were 30 a minute, changing at times to the Cheyne-Stokes type. There was marked dyspnea and diaphragmatic breathing. Tracheal râles were heard over the lungs. The mouth was open, the tongue swollen and congested. The patient was able to swallow fluids. Mucus tended to collect in the throat, and increased the degree of dyspnea and cyanosis already present. The abdomen was negative. The urine and feces were passed involuntarily.

Laboratory Data.—Examination of the blood revealed: erythrocytes, 4,450,000; hemoglobin (Dare), 93; smear, nor-

1. Littell, J. J.: Veronal (Barbital) Poisoning, J. A. M. A. **77**: 1333 (Oct. 22) 1921.
2. Hassin, G. B., and Wien, M. S.: Case of Acute Veronal (Barbital) Poisoning Simulating Epidemic ("Lethargic") Encephalitis, J. A. M. A. **75**: 671 (Sept. 4) 1920.
3. Taub, S. J.: Acute Veronal Poisoning, J. A. M. A. **74**: 459 (Feb. 14) 1920.
4. Macleod, Ernest: Med. Rec. **98**: 985 (Dec. 11) 1920.
5. Boenheim, F.: Acute Barbital Poisoning, Med. Klin. **17**: 1263 (Oct. 16) 1921; abstr., J. A. M. A. **78**: 76 (Jan. 7) 1922.